

Condensed Notes of the ASCRS Textbook

Allen Kamrava, M.D. M.B.A.

Fellow, Colon and Rectal Surgery

Table of Contents

1 Anatomy & Embryology of Colon, Rectum & Anus	5
2 Physiology: Colonic	9
3 Anal Physiology	10
4 Physiologic Testing	11
7 Endoluminal Ultrasound	13
8 Preop Mgmt – Risk Assess, Eval & Bowel Prep	14
9 PostOp Mgmt: Pain, Anesthesia, Fluids & Diet	15
10 POSTOPERATIVE COMPLICATIONS	16
11 Benign Anorectal: Hemorrhoids	17
12 Benign Anorectal: Anal Fissure	18
13 Benign Anorectal: Abscess and Fistula	19
14 Benign Anorectal: Rectovaginal Fistulas	20
15 Pilonidal Disease & Hidradenitis Suppurativa	22
16 Perianal Dermatology and Pruritis Ani	23
17 Sexually Transmitted Diseases	24
18 Benign Colon: Diverticular Disease	26
19 Colonic Volvulus	28
20 Lower Gastrointestinal Hemorrhage	29
21 Endometriosis	30
22 Colon and Rectal Trauma and Rectal Foreign Bodies	31
23 Colorectal CA: Epidemiology, Etiology & Genetics	32
24 Screening for Colorectal Neoplasms	33
25 Polyps	34
26 Polyposis Syndromes	36
27 Colon Cancer Evaluation and Staging	38
28 Surgical Mgmt of Colon Cancer	39
29 The Preoperative Staging of Rectal Carcinoma	40
30 Surgical Treatment of Rectal Cancer	41
31 Adjuvant Therapy for Colorectal CA	42
32 Colorectal CA Surveillance	43
33 Mgmt - Local Advanced/Recurrent Rectal CA	44
34 Colorectal CA: Metastatic (Palliation)	45

35 Anal Cancer	46
36 Presacral Tumors	48
37 Miscellaneous Tumors	49
38 Hereditary Nonpolyposis Colon Cancer	51
39 IBD: Diagnosis & Evaluation	53
40 Medical Mgmt of Inflammatory Bowel Disease	54
41 Surgical Management of Ulcerative Colitis	56
42 Surgery for Crohn’s Disease	57
43 Less –Common Benign Colorectal Disorders	58
44 Intestinal Stomas	62
45 Stoma Complications	63
46 Incontinence	64
47 Rectal Prolapse	66
48 Constipation	67
49 Pelvic Floor Disorders	69
51 Pediatric: Hirschsprung’s and others Conditions	70
54 Critically Reviewing Literature	73
Ileoanal Pouch Procedure for UC & FAP	74
Ligation of Intersphincteric Fistula Tract (LIFT)	75
Gracilis Flap Notes	75
Rectocele Repair with Mesh	75
Sacral Nerve Stimulation for Fecal Incontinence	76

This is a collection of the notes I made from the ASCRS textbook in preparing for the annual CARSITE exam. In of themselves, they are not enough to prepare for the CARSITE exam. I would highly suggest also referring to the material from the CARSEP review as it too was very useful in preparing for the exam. Combined with my readings from the ASCRS textbook as well as a complete and thorough review of the CARSEP, I was very pleased with my performance on the CARSITE exam.

I make no attestation to the comprehensiveness of these notes. There may be chapters or topics that I ought to have included more information on. As these are my notes, there are numerous typos that my word processor is absolutely useless in capturing with its spell checker. Ultimately, these are my own notes, so I have not taken the pain staking time of fixing every typo in them. I apologize in advance for any and all such errors, especially any that some would consider “embarrassing.” (I typo’d that for emphasis)

I do not know if this collection of notes will be helpful to others. What I can only hope for, is that it allows for either a good building block to take further notes upon, or a quick reference when reviewing topics. Indeed, there are things that later I looked up in other refernces, since what I have summarized from the ASCRS textbook is too brief.

There are a few chapters that are omitted. That was a personal choice. These were topics that, though interesting, I did not feel necessary to include in my set of review notes. This is not because the chapters were poorly written, but in my haste to complete these notes in time to study for the CARSITE exam, I did not believe they had information that would be tested on.

I also wish to take this time to thank my attendings at UPenn for the truly rewarding experience they have provided me this year. From the start, they have treated me as a colleague and have only bolstered my career at every possible opportunity. As much as I moan about the NRMP match process, I thank it for having matched me at this outstanding fellowship program. I would not have it any other way. For any residents considering a career in colon and rectal surgery, I can only give my highest recommendation to matriculating at UPenn.

All the best,
Allen

1 Anatomy & Embryology of Colon, Rectum &

Anus

Anatomy – Anus

Anal Canal Structure, Anus and Anal Verge

- Anal Orifice: Anteroposterior cutaneous slit
- Remains closed due to:
 1. tonic circumferential sphincter contraction
 2. anal cushions
- **Anocutaneous line of Hilton:** Anal Verge/Margin
- Anal Verge to Dentate line: ~1-2 cm

Anatomic vs. surgical Anal Canal

- Anatomic: 2 cm long, anal verge to dentate line
- Surgical: 4 cm long, anal verge to anorectal ring (levator ani)
 - to level of ampullary part of rectum & region of anorectal angle – corresponds w/ manometry & EUS

Anatomic Relations of the Anal Canal

- Anterior: perineal body, vagina (f)/Urethra(m)
- Posterior: Coccyx
- Lateral: Ischium & Ischiorectal Fossa

Muscles of the Anal Canal

- 3 functional groups
 1. Lateral Compression: Pubococcygeus
 2. Circumferential Closure: Sphincters
 3. Angulation: Puborectalis

Internal Anal Sphincter

- is the distal 2.5-4.0 cm condensation of circular muscle of the rectum
- smooth muscle in state of continuous contraction
- on EUS: 2-3 mm, hypoechogenicity

External Anal Sphincter

- Striated M., Elliptical Cylinder, Ends more distal
- 3 divisions: subQ, Superficial, Deep
 - Deep related to Puborectalis
- EUS: Ext. Sphinc + PuboR - 6 mm, hyperechogenic
- voluntary control of, maximum voluntary contraction can be sustained for 30 – 60 seconds
 - maintain unconscious resting electrical tone through a reflex arc at the cauda equina level
 - Ex. Sphi, PuboR, Levators: predominance of type I – connecting tonic contractile activity

Conjoined Longitudinal Muscle

- Confluence of outer longitudinal layer of rectum and levator ani muscle, travels via intersphincteric plane
- most distal end: **corrugator cutis ani muscle**
- gives perforating branches through internal the contribute to smooth muscle of submucosa (musculus cnalis ani, sustenator tunicae mucosae, Treitz muscle, musculus submucosae ani)
- Fxn: attaches anorectum to pelvis; binds int. & ext. sphincters

Epithelium of the Anal Canal

- Above Dentate Line: endoderm, mucosa, autonomic Nervous system
- Below Dentate Line: ectoderm, cutaneous, somatic nervous system
- **Pectinate Line:** (Dentate line) – remnant of *proctodeal* membrane.
- Anal Crypts (avg 6, 3-12); more concentrated in posterior half.
 - terminate in int. sphinc & inter. Sphin. Plane
- **Columns of Morgagni:** 8-14 – have their bases connected in pairs to each valve at dentate line
- Anal Papillae: at end of each column
- Mucosa: several layers of cuboidal cells
- deep purple color – internal hemorrhoidal plexus
- **Cloacogenic Zone** (Anal Transition Zone) – 0.5 – 1 cm above dentate line – strip of mucosa

ANATOMY – RECTUM

- Rectosigmoid Junction:
 - Anatomists: S3
 - Surgeons: Sacral Promontory
- Distal Limit:
 - Anatomosis: dentate line
 - Surgeons: Anorectal Ring
- 12-15 cm long, 3 lateral curves
 - upper and lower to right, middle to left
 - correspond to *Valves of Houston*
 - **Kohlrausch's Plica:** middle valve, most consistent in presence and location. Is the level of anterior peritoneal reflection.
- Peritoneal Relations:
 - Upper Third: Anterior and Lateral
 - Middle Third: Anterior
 - Lower Third: Entirely extraperitoneal

Anatomic Relations of the Rectum

- Posterior: mediana sacral vessels and the roots of the sacral nerve plexus

Fascial Relationships of the Rectum

Fascia Propria of the Rectum: extension of pelvic fascia, enclosing the rectum, fat & neurovasc. More evident posterior & laterally

Lateral Ligaments or Stalks: distal condensation of the pelvic fascia form ~triangular structure. Contains connective tissue and nerves, in 25% branches of middle rectal artery.

Presacral Fascia: covers concavity of the sacrum and coccyx, nerves, middle sacral artery, presacral veins

Rectosacral Fascia (Waldeyer's): anteroinferiorly directed thick fascial reflection from the presacral fascia at the S-4 level to the fascia propria just above the anorectal ring

Visceral Pelvic Fascia of Denonvilliers: thick fascia separates extraperitoneal rectum from anterior vagina/prostate.

- 3 structures between anterior rectal wall & prostate:

1. Anterior mesorectum
2. Fascia Propria
3. Denonvillier's Fascia

- 3 Planes of dissection:

1. Close rectal/preimuscular plane: inside the fascia propria, more bloody
2. Mesorectal Plane: most appropriate for rectal CA
3. Extramesorectal Plane: resection of denonvillier's fascia, places autonomic nerve plexuses at risk

Urogenital Considerations

- ureters rest on psoas muscle on inferomedial course
- crossed obliquely by spermatic vessels anteriorly and genitofemoral vessels posteriorly
- at pelvic brim, cross anteriolateral to iliac bifurcation

Arterial Supply of Rectum and Anal Canal

Superior Hemorrhoidal Artery: from IMA into Rectum at S3

- continues down to RA, RP and LL hemorrhoidals

Middle Hemorrhoidal A.: variability in reports of how often

- from ant. Division of internal iliac.
- reaches lower third of rectum anterolaterally, deep to levator fascia

Inferior Hemorrhoidal A.: internal pudendal – to int iliac A.

- 85% posterior commissure was less well perfused

Venous & Lymphatic Drainage of Rectum & Anal Canal

Lymph:

- upper 2/3: to inf. mesenteric & then paraaortic nodes
- Lower 1/3: to upper nodes (IMA & aortic) but also laterally to internal iliac nodes
- Below dentate: Superficial Inguinal Nodes
- In Women:
 - to 5 cm above anal verge: drain to posterior vaginal wall, uterus, cervix, broad ligament, fallopian tubes, ovaries, cul-de-sac
 - to 10 cm above: only to broad lig & cul-de-sac

Innervation of the Rectum

- Sympathetic Supply: rectum & left colon from L1-3
- Presacral Nerves: just below sacral promontory
- Hypogastric Nerve: sympathetic innervation from hypogastric plexus to pelvic plexus
- Pelvic Plexus: lateral side of the pelvis at level of lower 1/3 of rectum
- Parasympathetic Supply: from S2-4, AKA nervi erigentes

- join hypogastric nerves at pelvic plexus

- Combined autonomic nerves from pelvic plexus supply left colon and upper rectum via inferior mesenteric Plexus, and directly to lower rectum and anal canal
- Periprostatic Plexus: in Denonvillier's fascia, supplies prostate, seminal vesicles, corpora cavernosa, vas, urethra, ejaculatory ducts, and bulbourethral glands
- All pelvic nerves lie in plane b/n peritoneum and endopelvic fascia

High risk point of dissection to nerves:

1. High ligation of IMA (symp. Paraortic N.)
2. Sacral Promontory: Hypogastric N./Plexus
 - para still intact – retrograde ejac & bladder dysfxn
3. Level of Middle Hemorrhoidal: nervi erigentes
 - injury: complete impotence
4. Pelvic plexus on lateral portions
5. Denonvillier's Fascia: prostatic plexus

Innervation of the Anal Canal

Internal Anal Sphincter:

- Sympathetic: L5
- Para: S2-4

External Anal Sphincter:

- Inferior rectal branch of S2-3
- Perineal Branch of S4
- cross over of fibers, so unilateral ligation, still may preserve function from other side

Anal Sensation: inferior rectal branch of pudendal nerve

- Meissner's Corpuscles: touch
- Krause's Bulbs: cold
- Golgi-Mazzoni Bodies: pressure
- Genital Corpuscles: Friction

Anorectal Spaces:

Ischioanal, perianal, intersphincteric, submucosal, superficial postanal, deep postanal, supralevator, retrorectal space

Pelvic Floor Musculature

Anal Sphincter Complex:

- embryologic derivation: sphincteric cloaca group
- present in all mammals, ventral & dorsal components

Pelvic Floor Muscles:

- embryologic derivation: lateral compressor cloaca g.

Osseous Pelvic Side Wall Muscles:

- Obturator internus & Piriform

Levator Ani Muscle

Pelvic floor, major component of it.

3 Striated Muscles:

1. Ileooccygeus: ischial spine – S3,4 coccyx

- 2. pubococcygeus: pubis to S4&C1
 - 3. Puborectalis: U shaped around rectum
 - (4. Ischiococcygeus/coccygeus – rudimentary)
 - supplied by S2-4 sacral roots & perineal branch of pudendal nerve
 - puborectalis also: innervations from Inf. Rectal Nerves
 - *Levator Hiatus*: rectum, urethra, vagina pass through
- The Anorectal Ring and Anorectal Angle
- Anorectal Ring*: strong muscular ring – upper end of the sphincter (puborectalis) around anorectal junction
- division of this structure – fecal incontinence
- Anorectal Angle*: due to puborectalis U-shape
- helps maintain continence

ANATOMY - COLON

General Considerations:

About 150 cm long, cecum 7.5 cm, sigmoid 2.5 cm

Taeniae Coli:

1. Taenia Libera: Anterior
2. Taenia Mesocolica: Posteromedial
3. Taenia Omentalis: posterolateral

Haustra: outpoching between taeniae

Appendices Epiploicae: appendages of fat from serosa

Cecum

- 3 pericecal recesses or fossae: superior & inferior ileocecal and retrocecal
- formed by sup. & inf. Ileocecal ligaments

Ascending Colon:

- ~15 cm long
- Jackson's Membrane: fragile adhesions between right abdominal wall and its anterior aspect

Transverse Colon:

- ~45 cm long

Descending Colon:

- ~25 cm long

Sigmoid Colon:

- ~35-40 cm long

Collateral Circulation:

- *Marginal Artery of Drummond*
- *Griffith's Critical Point*: splenic flexure
- *Sudeck's Critical Point*: rectosigmoid
- *Meandering Mesenteric Artery*: if present, sign of atherosclerotic disease of SMA or IMA

Lymphatic Drainage:

4 Groups of Nodes:

1. Epiploic: bowel wall under peritoneum & appendices epiploicae
 - in rectum called: *nodules of Gerota*
2. Paracolic Nodes: along marginal artery
3. Intermediate: on primary colic vessels

4. Principle: on SMA or IMA

Innervation:

Right Colon: T7-12

Left Colon: L1-3

ANAL DEFECTS

Anal Stenosis: posterior shift in the position of the urorectal septum during its descent at the 6th week of fetal life

- 25-39% infants born with it, but by 3-6 months, over 75% spontaneously dilate

Membranous Atresia: "covered anus" – thin membrane. Likley from excessive posterior closure of the urogenital folds

Anal Agenesis: rectum extends below puborectalis and ends or fistulizes to anterior structure. Sphincter is present at normal site

Anorectal Agenesis: anus has dimple, sphincter normal, rectum ended proximally. Due to excessive obliteration of the embryonic tailgut. Most cases with fistula.

Rectal ("High") Atresia: rectum and anal canal are separated from each other by an atretic portion

Persistent Cloaca: rare, only in female infants. Total failure of the urorectal septum to descend at very early stage of development.

COLON DEFECTS:

Nonrotation: entire small bowel on the right. May be asymptomatic, or results in vascular compromise

Malrotation: cecum fails to complete 360 degree rotation. Cecum ends up in RUQ w/ lateral bands of adhesions. Bands can overly distal part of duo and cause obstruction.

Reversed Rotation: rotated clockwise instead of counterclockwise. Transverse colon posterior and duo anterior in relation to SMA

Omphalocele: retention of the midgut in the umbilical sac as a failure of gut to return to peritoneal cavity

Incomplete attachment of Cecum: may lead to cecal volvulus.

Internal Hernias Around Ligmanet of Treitz: from abnormal fixation. Most common internal hernias resulting from abnormal fixation of colon are right and left paraduodenal hernias.

Proximal Colon Duplications:

1. Mesenteric Cysts: lie in mesentery of colon
2. Diverticula: heterotopic gastric or pancreatic mucosa
3. Long Colon Duplication: Share a common wall

Meckel's Diverticulum: remnant of vitelline or omphalomesenteric duct, anti-mesenteric border of ileum, w/in 50 cm from ICV

- Littre's Hernis: herniation of this

Atresia of Colon: due to vascular accident. Three types, membranous, cord like remnant, complete separation

Hirschsprung's disease: absence of ganglionic cells in the myenteric plexus. Internal sphincter involved in all cases.

2 Physiology: ColonicEmbryology:

- Endoderm: epithelial lining (mucosa)
- Mesoderm: muscular and peritoneal components
- intestine rotates 270 degrees counterclockwise around SMA axis
 - bowel herniated outside abdomen and at end of third month, return and complete rotation.

Innervation:Parasympathetic:

- predominantly excitatory for colon's motor component via Ach and tachykinins (substance P)
- proximal colon via posterior vagal trunk w/ arterial blood supply
- Distal Colon: S2-4 from pelvic plexus

Sympathetic:

- inhibits colonic peristalsis
- effector cells from T & L spine
 - Greater: T4-T10
 - Lesser: T9-T11
 - Least: T11-L1
 - Lumbar input: L2,3
- plexuses around mesenteric arteries

Myenteric Plexus: smooth muscle function

Submucosal Plexus: modulates mucosal ion transport and absorptive functions

Important Neurotransmitters: Ach, Opioids, NorEpi, Serotonin, Somatostatin, CCK, Subs. P, VIP, Neuropeptide Y, NO

COLONIC FUNCTION:Salvage, Metabolism, and Storage

- Processes certain starches & proteins
 - via fermentation from bacteria that feed on: mucous, residual proteins, complex carbs
 - produce short chain fatty acids 95% absorbed in colon
 - principle ones: acetate, propionate, butyrate
 - most of this in Right and T colon
 - protein fermentation in left colon
 - Dietary fat not absorbed to any degree in colon
- Colonic Mucosa unable to nourish via bloodstream
 - nutrient requirements from luminal contents
 - *Butyrate* is primary energy source
 - *Propionate*: combines in liver for gluconeogenesis
 - *Acetate*: used by liver to for longer-chain FAs & muscle energy source
- Haustra function in mixing contents to form solid stool

Transport of Electrolytes

- efficient at conserving sodium and water
 - 1-2 L H₂O challenge daily, absorbs 90%
 - emits 100-150 ml fluid in stool daily
 - if needed, can increase absorption to 5-6 L daily
- Important for recovery of salts
 - Normally absorbs Na & Cl⁻

- and secretes: NaHCO₃ & K⁺

- Sodium Concentration > 25 mmol/L to absorb, otherwise it is secreted. Normal concentration 130-140 mmol/L (active transport)
 - Aldosterone causes increased absorption
- Chloride: exchanged for bicarb at luminal border of mucosal cells to act as neutralizing agent
 - passive absorption, due to active Sodium
- Potassium: secreted, 50-90 mmol/L in stool

COLONIC MOBILITYMarker

Capsule with 24 markers and X-ray on Day 5.

- 80% of markers should be expelled

Total colonic Transit time in hours:

- 30.7 for men, 38.3 for women

Scintigraphy:

- capsule coated with pH-sensitive polymer containing ¹¹¹In-labeled radioisotope ingested
 - coating dissolves in TI
 - images with gama camera

Recording Techniques of Colonic Motility

Probe placed into cecum and measurements taken
Various methodologies

Peristalsis

- Bassotti et al. defined classification system:
 1. segmental contractions – single or burst; rhythmic or arrhythmic
 2. propagated contractions – low vs. high amplitude contractions
 - High: ~5x a day, purpose to move things distally
 - Low: less is known. Related to sleep-wake cycle and meals. May be related to flatus.

Cellular Basis for Motility

Circular Muscle, Longitudinal Muscle, Interstitial Cells of Cajal (ICC)

ICC: pacemaker cells of the gut, mesenchymal cells.

Electrically active, create ion currents for pacemaker function.

Slow waves of circular and longitudinal muscles cells are in phase

Characteristics of Colonic Motility in Health

- Circadian rhythm, diminished activity at night, 3x increase when awakened in morning.
- Pressure increases after meals, for up to 2 hours
- Rectosigmoid region most active.

Defecation and Colonic Sensation

- *pre-expulsive*: entire colon, up to an hour before,

3 Anal Physiology**SPHINCTERS**

IAS – involuntary

EAS – voluntary

Anal Resting Pressure:

- IAS: 55%
- Hemorrhoidal Plexus: 15%
- EAS: 30%

REFLEXESCutaneous-anal Reflex

- brief contraction of the anal sphincter in response to pricking or scratching the perianal skin
- Spinal Reflex, requires intact S4
- if a Cauda Equina lesion present, reflex lost
- response to perianal scratch fatigues rapidly, so important to interrogate at beginning or exam
- may be used to evaluate incontinence, however conflicting views on its true implications

Cough Reflex

- Visible contraction of subQ EAS in response to cough
- preserved in paraplegic above lumbar spine, lost in those below
- keeps continence with increased abdominal pressure

Bulbocavernosus Reflex

- sensation of pelvic floor contraction elicited by squeezing the glans penis or clitoris
- will be prolonged by various disorders affecting the S2-S4 segments of the spinal cord

Rectoanal Inhibitory Reflex (RAIR)

- relaxation of the IAS in response to distension of the rectum.
- permits fecal material to come into contact with specialized sensory receptors in the upper anal canal
- Sampling process, determines quality of material
- allows to expel gas vs. stool
- develops early in life
- intrinsic nerve, isolated from extrinsic nerves, so protected from hypogastric nerve transection
 - lost with Hirschsprung's Disease
 - can be lost with overzealous LIS
 - can be lost with circumferential myotomy
- Saigusa et al: 53% preserved RAIR after ileostomy takedown (96% before ostomy)
- Nearly abolished in early post op after LAR
 - 18% at 10 days after LAR
 - 21% at 6-10 months after LAR
 - 85% after 2 years after LAR
 - 53% of IPAA stapled at 2 years

Rectoanal Excitatory Reflex (RAER)

- the contraction of the EAS in response to rectal distention
 - likely from S2-4 parasymp
 - pudendal nerve block affects this, so likely involved

MECHANICAL FACTORS OF CONTINENCE AND DEFECATIONAnorectal Angle and Flap Valve

Originally thought to function as a flap valve, but studies have shown otherwise. Now considered to just be part of sphincter complex.

Reservoir

Rectum has capacity and compliance.

Normal Defecation

1. Need to defecate in CNS:
 - superior frontal gyrus and anterior cingulate gyrus
2. contents move into rectum causing distention
3. RAIR stimulated --- IAS relaxes → sampling
- 4a. No shit: EAS & levator ani contract → rectum relaxes
- 4b. Yes shit: glottis closes, pelvic floor muscles contract, diaphragm and abdominal wall muscles contract to increase abdominal pressure
5. Puborectalis relaxes, pelvic floor descends slightly. EAS relaxes and contents out.
6. Closing Reflex: sphincters contract and pelvic floor rises

PATHOLOGIC CONDITIONSIncontinence

Numerous pathologies

- *Keyhole deformity*: groove in the anal canal allowing the seepage of stool or mucus. Often after sphincterotomy for fissure. Seepage of stool/mucous

Suspected Enterocele or Rectocele

Sx: prolonged straining, w/ sensation of partial or complete blockage

Rectocele: >2cm of rectal wall out-pouching or bowing while straining

- obstructs anal orifice and/or diverticulum sequesters stool

Dyskinetic Puborectalis

Absence of normal relaxation of pelvic floor muscles during defecation, resulting in rectal outlet obstruction
Usually treated with biofeedback and bowel management

- Botulism toxin into puborectalis with limited success

4 Physiologic TestingMANOMETRY

- measures baseline rectum & anus pressures as well as reflexes to stimuli

Indications:

1. incontinence –localizes & quantifies sphincter defect
2. constipation
3. anorectal pain syndromes
4. evaluation of baseline before pelvic floor procedure

Equipment: water-perfusion vs. solid-state method

Technique:

- focus on distal 5 cm (sphincter complex)
- *Prep:* tap-water enema, Fleets' enema,
 - left lateral position, knees at 90 degrees
- *Calibration:* water-perfusion pressure method more
- *Resting Pressure:*
 - station pull through vs. continuous pull through
 - continuous tends to give higher pressure readings
 - 1 cm intervals, 10 seconds a piece
- *Squeeze Pressure:*
 - probe to 6 cm, patient squeezes for 3 sec and probe pulled back at 1 cm increments
- *Squeeze Duration:* probe positioned at site of highest pressure; patient to squeeze and hold for 45 seconds
- *Reflexes:*
 - RAIR: probe at highest pressure zone, probe balloon stepwise inflated; normal will show relaxation
 - normal RAIR excludes Hirschsprung's Dz
 - >25% of basal pressure response to rapid inflation
 - Cough Reflex: highest pressure zone, patient coughs and should see pressure increase to protect from stool
- *Strain Maneuver:* high pressure zone, bear down for 5 seconds,
- *Rectal Sensation:* balloon inflated in 10-cc increments until patient senses it, first normally at or before 20 cc
 - poor response predicts failure to biofeedback
- *Compliance:* now fill in 50-cc increments, till patient gets urge to defecate and then discomfort (200-250cc)

Interpretation:

- Normal Pressure Differences:
 - upper anus: anterior < posterior
 - mid anus: anterior = posterior
 - distal anus: anterior > posterior
- *Resting Pressure:* 75-80% by IS
 - Women: 52 mm Hg (39 – 65)
 - Men: 59 mm Hg (47 – 71)
 - low in incontinence, high in pain symptoms
- *Squeeze Pressure:*
 - Women: 128 mm Hg (83 – 173)
 - Men: 228 mm Hg (190 – 266)
 - low sphincter/nerve injury, high in anismus/pain
- *Squeeze Duration:*
 - importance not clear

- normal: squeeze >30 sec @ >50% of max squeeze pressure

DEFECOGRAPHY

A dynamic fluoroscopic exam w/ rectal contrast to study anatomy & fxn of pelvic floor during defecation. Low radiation exposure.

Indication: outlet obstruction type of constipation

Interpretation:

- *Anorectal Angle:* angle b/n mid-axial longitudinal axis of the rectum and the anal canal; 90 – 110 degrees
 - decreases during squeezing; 75 – 90 degrees
 - increases w/ defecation and straining; 110 – 180°
- *Perineal Descent:* caudad mov't of pelvic floor w/ straining
 - **pubococcygeal line:** line from tip of coccyx to under pubis
 - Normal: rise with squeeze, lower w/ straining/evac
 - no more than 4 cm in either direction
 - abnormality, may suggest Pudendal N. Injury
- *Anal Canal Length:* width should not be <2.5 cm; if so may indicate incompetent muscles
- *Efficiency of Emptying:* 90% is lower limit of normal (100% normal); If Ileal pouch, 60% lower limit of normal
- *Rectocele:* bulging of rectum into post wall of vagina
 - generally, < 3cm not of consequence
- *Enterocoele:* abnormal for bowel to descend below the upper rectum, and it is abnormal for a space to be present of > 2 cm between the rectum and vagina
- *Anismus:* non-relaxing puborectalis or levator muscle complex – fixed anorectal angle; causes pain
 - takes >30 seconds to evac, normal <10 sec
- *Megarectum:* > 9 cm

BALLOON EXPULSION TEST

Measures the ability of the patient to expel a balloon inflated with 50-60mL of water. Not very sensitive or specific.

- evals for outlet obstruction – can't pass balloon

ANAL ULTRASOUND

Looks for anatomic abnormalities of sphincters;

- ~100% sensitivity

Interpretation – layers:

- 1) Hyperechoic: interface
- 2) hypoechoic: mucosa
- 3) Hyper: submucosa
- 4) Hypo: internal anal sphincter
- 5) Hyper: intersphincteric plane & longitudinal muscle
- 6) layer of mixed echogenicity – external sphincter

MRI

Indications: sepsis, trauma, congenital abnormalities, tumor

EMG OF ANAL SPHINCTER

Primarily to evaluate fecal incontinence – tests:

- 1) integrity of muscle
- 2) integrity of nerve supply

Concentric Needle EMG

- particular value in the diagnosis of specific neurologic problems, including conditions of the cone and cauda equine, sacral roots, pudendal nerve and for differential diagnosis of the various types of multisystemic atrophy.
- Normal amplitude of the MUP is < 600 μ V
- Normal duration of the MUP is <6 ms

Single Fiber EMG

- 20 needle positions on external sphincter
- Value >1.7 abnormal
- Criteria for pudendal nerve damage:
 - presence of increased fiber density
 - increase of MUP duration & amp at rest
 - decreased MUPs during max contraction
 - “jitter and blocking” phenomenon

Surface Electrodes:

- document anal sphincter activity at rest, strain and squeeze
- can be used with biofeedback training
- do not want to see paradoxical activity

Pudendal Nerve Terminal Motor Latency

- Pudendal nerve origin: S2-4
 - lateral pelvic wall (near ischial spine) → supplies ES & periurethral muscles (via terminal perineal branch)
 - records latency of stimulation from pudendal nerve → reflects the myelin function of the peripheral nerve
 - normal PNTML does not exclude partial damage

EVALUATION OF TRANSIT

Food diary for 4 weeks for: fiber, fat, calorie intake

Colonic Transit

- Normals: total colon – 35 hours
 - Right: 11.3 hours
 - Left: 11.3 hours
 - Rectosigmoid: 12.4 hours
- Stool weight correlates with transit in constipated
- by use of radiopaque markers
 - One capsule with 24 markers on Day 0
 - Supine AXR on Day 5: number & locations of them
 - 5 or less remain = normal colonic transit
 - Diffuse Scattering: colonic inertia/decreas'd motility
 - Markers in rectosigmoid: pelvic outlet problems

Radionuclide Transit

- gamma scintigraphic techniques
- 24 – 48 hours of scanning only (not 5-7 days)

Small Bowel Transit

- breath hydrogen analysis
 - test for ppm of hydrogen in lungs
 - Time to 20-ppm

7 Endoluminal Ultrasound

Enorectal Ultrasound

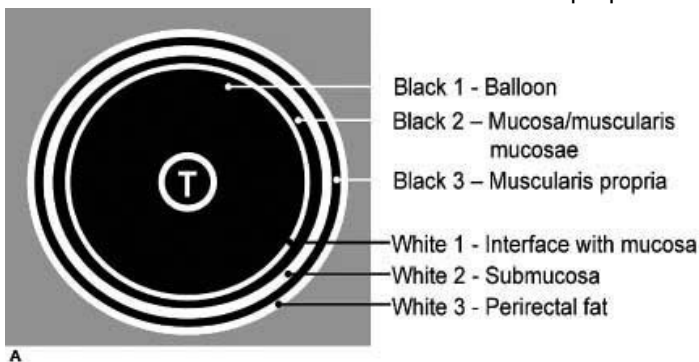
Equipment and Technique

- 7- or 10-Mhz transducer (10 preferred)
 - focal lengths of 2-5 or 1-4 cm respectively
- Latex balloon around the probe with water instilled to insufflate and maintain contact between probe and rectal wall

Image Interpretation

5 distinct layers to identify in rectal wall.

1. White Line: Interface of probe with rectal mucosa
2. Black Line: Mucosa and muscularis Mucosae
3. White Line: Submucosa
4. Black Line: Muscularis/Fascia Propria
5. White Line: Perirectal Fat border w/ fascia propria



Source: Kaiser AM: *McGraw-Hill Manual Colorectal Surgery*:
<http://www.accesssurgery.com>

Copyright © The McGraw-Hill Companies, Inc. All rights reserved.

Staging:

- uT0: benign, confined to mucosa
- uT1: invasive confined to submucosa
- uT2: into but not through the fascia propria
- uT3: through fascia propria into perirectal fat
- uT4: into adjacent organ

Nodal Involvement

- sensitivity: 50-80% in detection
 - Inflammation: hyperechoic (white)
 - Malignancy: hypoechoic (black), >5 mm in size
- uN0: undetectable or benign lymph nodes
- uN1: detectable lymph nodes
- many lymph nodes <5 mm may not be detectable but can still harbor CA (20-50% of time)

4 patterns of lymph nodes on ERUS:

1. Nonvisible: likely no nodal involvement
2. Hyperechoic: benign, inflammatory
3. Hypoechoic, > 5mm: metastases
4. Mixed echogenic >5mm: treat like nodal mets

EndoAnal Ultrasound

Equipment and Technique

- 7- or 10-Mhz transducer (10 preferred)
 - focal lengths of 2-5 or 1-4 cm respectively
- Plastic cap filled w/ H₂O, pinhole in tip to allow air to escape

Image Interpretation

Puborectalis: marker of upper anal canal – mixed-echogenic structure forming the lateral and posterior portion of the upper canal

Mid Anal Canal:

- IAS: hypoechoic band
- EAS: Hyper-echoic ring, variable thickness (epithelial, hmoerrhoidal and submucosal tissues)

Perineal Body Thickness: normal 8-15 mm

- in the mid-anal canal, place finger and push against the probe on rectovaginal septum. Distance between IAS and hyperechoic reflection of finger

Eval of Perianal Sepsis and Fistulas

- can be used for complex fistulas to assist in delineating the tract
- Hydrogen Peroxide will enhance imaging – will appear hyperechogenic, increases sensitivity to 90%

For Anal Cancer Staging

- uT1: confined to Submucosa
- uT2a: invades only IAS
- uT2b: penetrates into EAS
- uT3: through sphincters into perianal tissues
- uT4: invades adjacent structures

8 Preop Mgmt – Risk Assess, Eval & Bowel PrepSCORING SYSTEMS – RISK ASSESSMENTGoldman Cardiac Risk Assessment

- best-accepted model, 9 clinical factors
- four risks classes
- MI <6mo, Age>70, JVD or S3, arrhythmia, PVCs, Emergency op, Thoracic/abdominal/aortic op, overall medical condition

American Society of Anesthesiologists Class (ASA)

- correlates w/ ICU stay, blood loss, vent duration
- I: normal, healthy
- II: mild systemic disease
- III: sever, systemic disease
- IV: incapacitating, threatening life
- V: moribund, unlikely to live >24h
- E: Emergency

APACHE (Acute Physiologic & Chronic Health Eval) Score

- designed for ICU patients;
- does not account for nutrition, cardiac status, extent of surgery

POSSUM Score

- Physiological & Operative Severity Score for enumeration of Mortality and Morbidity
- via multivariate analysis, used for auditing
- does not use primary diagnosis as factor
- over predicts mortalities that are in the 1% range

P-Possum Score

- new model to reduce the overprediction of mortality

Preop Cardiac Eval?

Don't need to do if:

- Asymptomatic patient w/ normal cardiac stress test w/in 2 years
- Hx of CABG in last 5 years
- stable patient w/ angioplasty w/in 6 mo to 5 years
 - if angioplasty <6 mo – speak with cardiologist

Nutritional Assessment

- loss of 10% of body weight in 6 months or alb <3
- higher risk of complications, may benefit from 2 weeks of preop nutritional supplements

BOWEL PREPARATION

To do or not to do?

- 7 studies reviewed, 3 showed worse anastomotic leak rate with MBP, 4 showed no difference

9 PostOp Mgmt: Pain, Anesthesia, Fluids & DietPAIN CONTROL

JCAHO requires specific assessment & documentation

Physiology:

Nociceptive signals carried by A delta and C fibers to the Dorsal horn of the spinal cord & to Ascending path to CNS

- once sensitized, threshold for stimulation lowered and firing rate is increased

Opioids:

- block transmission of nociceptive afferent signals in the spinal dorsal horn & involve efferent messaging by activating inhibitory pathways supraspinally
- Act locally in the areas of tissue injury to inhibit inflammation

Side Effects: resp. depression, pruritis, N/V, constipation

- *Meperidine:* worse analgesia than morphine, shorter half life, causes CNS excitation, increased Resp Depression, more addictive, neurotoxic potentials; discouraged use by JCAHO

NSAIDs

- inhibit COX in periphery and in the spinal cord
 - action mediated by COX-2: analgesia & antiinflam
 - Side effects by COX-1 effects: GI tract, renal, platelets
- risk of side effects in: age >75, dose over 105 mg/day, course longer than 5 days

Antihistamines:

- known to activate nociceptive fibers and may participate in mediating pain
- mechanism of action not really known
- studies conflicting at this point

Epidural Anesthesia:

- function at the dorsal horn preventing afferent conduction of nociceptive stimuli
- better pain control, patient satisfaction, decreased ileus

Pre-Emptive Analgesia:

- theory: preven intial stimuli that causes decreased sensation
- multiple studies found that the not really effective

PERI-OPERATIVE FLUID MGMT

2500 cc/day in 70 kg adult

- 1500 cc of urine necessary daily
- to calculate: 1500 cc first 20 kg, then 20 cc/kg for rest
- Surgical stress → increased renin, aldosterone, ADH → 3rd spacing (fluid sequestration)
- 2 randomized studies: relative fluid restriction had fewer complications, quicker resolution of ileus

ULCER PROPHYLAXIS

In patients without risk of personal history – not necessary

DVT PROPHYLAXIS

66% of DVT will occur within 3 months after discharge

Elastic Stockings: graduated w/ decreased pressure proximal

- decreased DVT risk with moderate risk factors

SCDs: Mechanical & increase fibronolytic activity by reducing plasminogen activator

Low-Dose Unfractionated Heparin (LDUH):

- Risk of HIT (5-15%?) --- monitor platelets
- Q12 dosing unless higher risk

Low Molecular Weight Heparin:

- acceleration of ATIII inactivation of Xa, but does not inactivate thrombin
- greater bioavailability and half-life
- does not need to be monitored

DIET

Routine NGT post op not found to be beneficial

Recommend early feeding

STEROIDS

Overall effect: increase gluconeogenesis by allowing AA production via lipolysis and proteolysis

Physiologic production: 20 mg/day Cortisol

- Maximal Stress: 150 mg/day Cortisol

Can take up to 1 year to regain full adrenal function

- Adrenal insuff: is quite rare, anecdotal evidence (1952 2 case reports)
- for now, stress dose recommended until further evidence, quick taper over a few days
- essentially give stress dose to anybody taking prednisone 20 mg/d for over 3 weeks or longer

Steroid Doses Table

	Equivalency (mg)	Half-life (h)
Prednisone	5	18-36
Dexamethasone	0.5	36-54
Hydrocortisone	20	8-12
Methylprednisolone	4	18-36

10 POSTOPERATIVE COMPLICATIONSMISSED ENTEROTOMY/EC FISTULAS

EC Fistula: Complete bowel rest, Abx, CT to eval

- Pouch the fistula
- Somatostatin Analog: doesn't cure, just decreases output
- < 50% will close spontaneously – of those that do, will be within the first month

ANASTOMOTIC COMPLICATIONS

Usually due to technical factors or patient illness/disease

Steps to minimize this:

1. ensure good blood supply (pulsatile marginal A.)
2. Tension Free – complete mobilization, high ligation of IMA, IMV ligated at inferior pancreatic border
3. Avoid Sigmoid Colon in Anastomosis
4. Inspect Donuts
5. Air or fluid insufflation tests

BLEEDING

Use antimesenteric border to minimize

If pouch or coloanal anast. Bleed: rectal tube and 1:100,000 solution of saline + epi for 15 minutes

LEAKS

Small Bowel/ileocolic: 1-3%

Coloanal: 10-20%

Steroids, DM, low anastomosis as risk factors

Pelvic Drains: Dutch TME trial reduced leak from 23% to 9%

GENITOURINARY COMPLICATIONSUreteral Injuries:

- 4 danger points of injury:
 1. High ligation of IMA
 - 1° repair usually ok here
 2. Mobilization of mesorectum at promontory
 - 1° vs. Boari flap v. Psoas Hitch
 3. Low anterolateral dissection/lateral stalks
 4. Cephalad portion of perineal portion
- Ureteroneocystostomy: tunnel the ureter through the bladder wall and create a mucosa to mucosa anastom.

Urethral Injuries:

- during APR at membranous or prostatic portion
- small injury: 5-0 chromic suture & foley 2-4 weeks
- Larger Repair: urology eval, delayed repair with diversion

Bladder Injury:

- 2 layer repair, foely for 7-10 days w/ cysto just prior

Urinary Dysfunction:

- 70% of patients low pelvic operation
- Due to: denervation of the detrusor muscle causing partial paralysis

- parasympathetic control via pelvic nerve branches from inferior hypogastric plexus

- most improve after 5-7 days, few months

Sexual Dysfunction:

- 15-50% males after APR
- *Retrograde Ejaculation:* damage to superior hypogastric (sympathetic) nerve plexus during high IMA ligation or sacral promontory dissection
- most resolve by 6-12 months

Erectile Dysfunction: damage to the pelvic plexus during lateral dissection or to the nervi erigentes or cavernous nerves while dissecting the anterior plane

Female Infertility:

- 50% in total proctos

Trapped Ovary Syndrome:

- adhesions after IPAA
- each ovulatory cycle, release of fluid into cavity defined by these adhesions
- fluid accumulates, cavity expands
- will complain of pelvic or lower abdominal pain relevant to the side of the trapped ovary
- Treatment: unroofing and evacuation of the cyst, pelvic adhesiolysis, and suspension of the ovary to the pelvic brim or iliac fossa with sutures.
- Prevention: suspending the ovaries at the time of restorative procto and by placement of an adhesion barrier film in the pelvis

PELVIC BLEEDING

Usually due to injury to presacral venous plexus or the internal iliac vessels/branches

Presacral Plexus:

- Coag and suture ligation usually worsens it
- Finger pressure to gain temp control
- Sterile Thumbtacks
- occlude pins
- Rectus Abdominus Muscle Flap
- may need to do damage control with packing

11 Benign Anorectal: Hemorrhoids

Only 5-10% will need operative hemorrhoidectomy

ANATOMY

- *Treitz Muscle*: anal submucosal muscle
- *Vascular Cushions*: anal continence, protect sphincters (15% contribution), are part of normal physiologic function
- *3 main cushions*: L. Lateral, R. Ant, R. Post. (in 19%)
 - most will have additional small accessory cushions

ETIOLOGY: Constipation, straining, irregular habits, diarrhea, pregnancy, erect posture, increased abdominal pressure, IAS abnormalities

EXAMINATION

- prone jack knife – if can't tolerate do sims position (left lateral)
- Side viewing Anoscopy best for hemorrhoidal disease

TREATMENT

3 categories

- dietary and lifestyle: 20-30 g/day fiber, Calcium Dobesilate,
- non-op, office procedures
- operative hemorrhoidectomy

Office Treatments*Rubber Band Ligation:*

- aim at least 2 cm above dentate line
- sloughs in 5-7 days
- 1st and 2nd degree, sometimes 3rd
- can do multiple in a single session
- avoid ASA or others 7-10 days

Infrared Photocoagulation:

- infrared radiation via a tungsten-halogen lamp
- coagulates tissue – apply 1-1.5 sec 3-4x per

Bipolar Diathermy:

- cautery, bipolar – in 1 sec pulses

Direct-Current Electrotherapy

- probe placed at apex of hemorrhoid
- 110-volt direct current for about 10 minutes
- requires multiple treatments

Sclerotherapy

- chemical agents injected – fibrosis and scarring
- 5% phenol in oil or 5% quinine and urea
- hypertonic saline
- 2-3 ml into submucosa of each >1 cm from dentate
- avoid repetitive injection – risk stricture formation

Anal Dilatation or Stretch:

- manual dilatation, risks sphincter injury, and high failure rate. Not advocated in the US

Cryotherapy

- freezing the Internals – special probe with NO at -60-80 degrees C. Very poor results. Not recommended.

External Hemorrhoids

Acute Thrombosis: peaks at 48 hours, subsides usually by 4th

- if pain intense, can consider resection
- if improving, then excise
- excision can be done in office (does NOT need OR)
 - can be in OR, but NOT mandatory
- excise entire thrombosed hemorrhoid
- can leave wound to close secondarily

Operative Hemorrhoidectomy

Milligan-Morgan Technique (Open): UK – excision of the external & internal components, leave skin to close secondarily over 4-8 weeks

Ferguson (Closed): excision of both, closure of the skin defects primarily

Whitehead Procedure: circumferential excision of veins and mucosa proximal to dentate line. Concern for ectropian.

Stapled Hemorrhoidectomy: more of a pexy, Expensive, so not practical for grades 1&2. Circumferential grade III is best candidate for this.

- circumferential purse string 4-6 cm above dentate
- stapler head introduced proximal to purse-string
- close for 20 seconds after firing
- does not excise – pexies

Strangulated Hemorrhoids

- rosette of thrombosed external and/or prolapsed internal
- urgent/emergent treatment
- excise all necrotic tissue – if there is necrosis, use open techniques

Hemorrhoids in setting of Portal Hypertension

- in these patients, serve as a collateral pathway
- rarely bleed, implicated in 1% of massive bleeding in these patients
- Rx: medical mgmt, suture ligation, stapled anopexy, TIPS< Shunts, IMV ligation, Sigmoid Venous to Ovarian Vein Shunt, IMV Shunt

Hemorrhoids in Pregnancy

- most will resolve
- so only do operation for acutely thrombosed/prolapsed
- try to do under local, in Sims position

Hemorrhoids and Crohn's Disease

- can do operation, just exercise caution
- high rate of sig. complication (30%)
- avoid in patients with active Crohn's anal Dz or proctitis

Hemorrhoids and Immunocompromised

- poor wound healing and infectious complications
- perform as a last resort to relieve pain and sepsis

PostHemorrhoidectomy Hemorrhage

- 2% rate
- most respond to packing or tamponade with a foley catheter balloon
- 15-20% will need suture ligation

12 Benign Anorectal: Anal Fissure**EPIDEMIOLOGY**

M:F = 1:1

90% posterior midline

- 25% of women, anterior midline
- 3% of patients ant & post

Lateral Fissures: consider other systemic etiology*Chronic Fissure*: 8-12 weeks – edema and fibrosis, sentinel pile, hypertrophied anal papilla proximal**ETIOLOGY**

Trauma from hard stool

Associated with increased resting anal pressure

- inverse relationship between pressure & perfusion
- 85% paucity of blood vessels in posterior midline
- blood flow increased w/ decreased pressure

SYMPTOMS

Pain during & after defecation

- short lived or lasts several hours
- razor blades vs. glass shards
- fear bowel movements

DIAGNOSIS

Patient History and exam

- if present, DRE & anoscopy not advised

If multiple or lateral, EUA warranted for better exam and possible biopsy

Differential: abscess, fistula, TB, STD, IBD, CA

MANAGEMENT**CONSERVATIVE**

50% heal w/ sitz baths & psyllium

- 20% rate of recurrence

OPERATIVE TREATMENTAnal Dilatation:

- Sohn et al: Park's retractor to 4.8 cm or a pneumatic balloon to 40 mm.
- reported 93% success rate
- Concern for incontinence from sphincter damage
- MacDonald et al: 27% rate

Lateral Internal Sphincterotomy:

- "Gold Standard" for anal fissure
- incontinence from 1.3% - 36% depending on study
- Littlejohn et al: No incontinence if LIS length of fissure
- Open vs. closed: Equivalent, but one study showed long-term persistent complications in Open group
- Gupta & Kalkasar: improved patients satisfaction with removal of hypertrophied polyps

Advancement Flaps:

- only one prospective trial to date. No significant difference in success b/n this and LIS

MEDICAL MANAGEMENTTopical Nitrates:

NO: predominant nonadrenergic, noncholinergic NT in the IAS → causes IAS relaxation

Success rates between: 20 – 90% on studies

- questioned by many if actually efficacious
- high recurrence rates reports
- advocated as first line therapy
- less likely to work in chronic fissures
- Side Effects: headache (63%) Lightheaded (52%)

Calcium Channel Blockers:

- 2% DTZ gel 3 times daily
- Side effects: dermatitis & headache
- topical gel found to be more effective the GTN and oral
- side effects less frequent than GTN
- data on long term recurrence lacking

Adrenergic Antagonists:

- alpha-1 adrenergic blockade
- 2 prospective trials
- trials not completed due to lack of efficacy

Cholinergic Agonists:

- 0.1% bethanechol gel tid for 8 weeks
- no side effects reported
- decreased resting pressures
- worked in 9 of 15 patients

Phosphodiesterase Inhibitors:

- area of possible research, no clinical data as of yet

Botulinum Toxin:

- binds pre-synaptic membrane.
- studies suggest sympathetic blockade
- can be given outpatient
- 2 injections of 20 U BT-A
- at 2 months: complete healing in 73%
- repeat injections healed 100%
- no recurrences at 16 months noted
- some recommend as 2nd line treatment, before LIS
- LIS better long term results, however high rate of complications
- long term recurrence high rate

SPECIAL SITUATIONSLow Pressure Fistulas:

- fissure in patients w/ low pressure should not have sphincter pressure reduction treatments
- correct treatment being evaluated
- *Island Flap*: one study to date, reported 100% success at 18 month follow up (Nyam et al, 21 patients)

Crohn's:

- ~30% Crohn's patients will have
- ~60% will heal during medical therapy for Crohn's
- ~10% will ultimately require operative therapy

HIV:

- very little data available
- Barret: 32% of HIV patients with Fissures

13 Benign Anorectal: Abscess and Fistula**ABSCCESS - Anatomy:**

Potential spaces: Perianal, Ischioanal, Submucosal, Supralelevator, Intersphincteric, Retrocecal, Deep Postanal, Superficial Postanal

Pathophysiology:

- 90% from cryptoglandular infection.
- 10% - Trauma, Inflammatory Dz, Malignancy
- Predisposing: Diarrhea & trauma from hard stool
- Class: termed by the space they occupy (above)

Evaluation and Treatment:

- Pain swelling, fever
- severe rectal pain w/ urinary Sx – possible intersphincteric or supralelevator abscess

TREATMENT:**I&D**

- *Horseshoe Abscess*: Hanley procedure to drain
- 3 incisions, Posterior midline & 2 counter incisions
- *Supralelevator Abscess*: drainage depends on origin of abscess, need to determine this first
- intersphincteric: drain via rectum to prevent fistula
- ischioanal: drain via perianal skin to prevent fistula
- Put incisions as close to anus to minimize the amount of involved tissue if a fistula develops

Antibiotics: little to no role, only for patients with valves or prostheses is it indicated

COMPLICATIONS:

Recurrence: up to 89%

Incontinence: if sphincters divided

FISTULA-IN-ANO

Defined: abnormal communication between two epithelium-lines surfaces.

Classifications

- (1) *Intersphincteric*: MC ~70%, anywhere w/in this plane
- (2) *Transsphincteric*: ~23%; usually from ischioanal abscess;
 - includes rectovaginal fistulas
- (3) *Suprasphincteric*: 5% from supralelevator abscess. Intersphincteric abscess that passes above puborectalis
- (4) *Extrasphincteric*: 2%; from rectum above the levators; usually due to trauma or inflammatory condition

Goodsall's Rule:

- Posterior: originate posterior midline
- Anterior: originate in nearest crypt

Treatments - General Principles:

- Eliminate fistula, prevent recurrence, & preserve sphincter fxn

Lay-open technique:

- for simple and low transsphincteric
- incision and curettage
- marsupialization optional

Seton: any foreign substance that can be inserted into the fistula tract to encircle the sphincter muscles.

- Lower portion of sphincter is divided
- Cutting seton: tension overtime to make track superficial

Anorectal Advancement Flap:

- no muscle divided
- full-thickness flap of mucosa, submucosa, and part of internal sphincter raised
- residual internal opening is closed.
- flap advanced 1 cm below internal opening
- Base of flap twice the width to maintain blood supply
- 90% success
- risks for failure: Crohn's and steroids

Fibrin Glue:

- non-invasive with no risk to sphincters
- if fails, can be repeated multiple times
- Fill entire tract with glue after curettage
- 60% success, 69% success in 2nd go at it

Bioprosthetic Fistula Plug:

- lyophilized porcine intestinal submucosal
- fistula tract not debrided for this
- clear tract with peroxide
- plug advanced through internal opening until "wrinkling" visualized, not forced tightly
- secure plug into place with 2-0 absorbable in figure of eight traversing through the plug
- good for long tracts without active sepsis
- not suitable for rectovaginal fistula

RECTOURETHRAL FISTULA

Sx: leakage of urine through rectum when voiding MC

Study: sigmoidoscopy, cystoscopy and RUG

- *Trans-Abdominal approach*: abdominoanal pullthrough with omental interposition.
- *Perineal Approach*: graicllis, dartos or Martius flaps
- *Anterior Trans-anorectal Approach*: midline perineal incision
- *Per-anal approach*: full-thickness advancement of rectal wall protectect by diverting colostomy
- *Kraske Laterosacral approach*: excellent exposure without division of sphincter muscles.
- *York Mason Approach*: rapid, bloodless exposure though fresh territory. Avoid neurovascular bundles.

14 Benign Anorectal: Rectovaginal Fistulas**Etiology:**

- 7 – 10 days after delivery (for OB related ones)
 - most often after 3rd or 4th degree lacs
 - inadequate repair, breakdown, or infection
 - 0.06% - 0.1% of vaginal deliveries in US
 - in developing nations higher prevalence due to prolonged labor → necrosis rectovaginal septum
- LAR – 2.9%
 - posterior vag wall included in anastomosis

Evaluation:

Two primary goals: identification & then assessment

Identification:

- may see dark red rectal mucosa vs. pink vag mucosa
- may see dimple anterior midline of rectum
- **Methylene Blue Test:** vaginal tampon, and then methylene blue enema. See if tampon gets blue
- **Vaginography:** contrast into vagina through a foley catheter w/ balloon up to occlude the vag orifice
 - 79 – 100 % sensitive
 - more useful for colovaginal and enterovaginal fistula
- MRI & Ultrasound:

Assessment:

- Symptoms of incontinence
 - 48% w/ these symptoms
 - 100% of post obstetric patients

Classification:

- size, location, etiology
- Daniels: low, middle or high, on rectvag septum
 - low: vaginal fourchette
 - high: cervix
 - middle: everything in between
- Simple vs. Complex system
 - simple: < 2.5 cm, low, 2nd to trauma/infection
 - complex: large, IBD / radiation / malignancy

Surgical Techniques**Local Repairs:**

- for 1st or 2nd repair w/ intact sphincter muscles
- prone jack knife, head light, lone star
- **Fibrin Sealant:** discouraging results (0-33%) of success
- **Advancement Flaps:** trans – rectal, -vag or -perineal
 - U-shaped flap includes the fistula within it. Base 2-3 times larger than apex. Raise proximal to 4-5 cm.
 - Debride tract, leave open to drain to vag. Advance and close, debride off distal end with fistula
- **Rectal Sleeve Advancement:** mobilization of distal rectum and advancement to cover the fistula

- circumferential at dentate line through submuc
- Full thickness at anorectal ring and above
- mobilize until at fully healthy tissue
- advance healthy tissue and do coloanal anasto
- **Noble-Mengert-Fish Technique:** Full thickness of anterior wall mobilized 180°, continue until at rectovaginal septum. Flap secured to external sphincter muscle.
- **Excision of Fistula with Layered Closure:** 88-100% works
 - excise the tract, and then do a layer by layer closure
- **Perineo-Proctotomy:** conversion to 4th degree lac.
 - tract is excised and both rectal and vag wall dissected aware from the muscle
 - Repair of both rectal and vaginal defects
 - External sphincter muscle reapproximated
 - Perineal body reconstructed and skin closed
 - 87 – 100% success rates
- **Inversion of Fistula:** vaginal mucosa mobilized circumferentially around the fistula. Tract is excised and a pursestring suture used to invert the fistula into the rectum. Vaginal wall closed over this inversion.
 - One small series report (n=47) 100% successful

Complex Repairs:

- **Tissue Interposition:**
 - MC sphincteroplasty
 - incision closed with drain in place
 - muscle mobilized and inserted b/n rectum & vag
- **Labial Fat Pad – Martius Graft:**
 - Bulbocavernous Muscle
 - longitudinal incision over labial majora
 - tunneled to final position
 - small series (14) 100% successful. Others ~80%
- **Tissue Interposition: Bowel**
 - LAR, Omental buttress
 - *Bricker and Johnston:* Sigmoid colon divided and hartmann's. Distal end anastomosed to rectum at level of fistula. After healing, colo-colo side to side anastomosis.

Choice of Treatment:

- **Secondary to Obstetric Injury:**
 - some close spontaneously
 - ~100% w/ sphincter defect
 - goal: close fistula and restore continence
 - choice of repair based on surgeon experience
 - author's: sphincteroplasty & perineoproctotomy
- **Secondary to Cryptoglandular Disease:**
 - EUS to exclude occult disease
 - advancement flap if no other etiology
 - otherwise, dealer's choice for what makes sense

- Secondary to Crohn's Disease:
 - medical mgmt. a primary
 - Non-cutting seton + infliximab. Remove seton before last dosing of infliximab. 3 infusions usually necessary
 - radiologic healing rate lower than clinical
 - may need infliximab longer
 - never due until proctitis first treated
 - If flaps, always divert
- Secondary to Malignancy:
 - depends on cancer
- Secondary to Radiation:
 - diversion for at least 6 months
 - if low – muscle interposition
 - if high – abdominal tissue interposition or rsxn
- Iatrogenic Fistulas:
 - High: repeat rsxn
 - Low: advancement flaps
- Persistent Fistulas:
 - many successful on 2nd go around
 - 3rd attempt usually not successful
 - 3 month minimum between attempts
 - interposition grafts and sphincteroplasty

15 Pilonidal Disease & Hidradenitis Suppurativa**Pilonidal Disease**

SubQ infxn in upper ½ of gluteal Cleft

M:F = 3.5:1

- During WWII: 79,000 soldiers, avg stay in hospital: 55d

- Risks: FamHx, Obesity, sitting, driver

Develops as recurring abscess and drainage – chronic before many seek help

Pathogenesis

- Acquired condition
- No published experiments exist that directly prove or refute the current theories of how the disease occurs

Initial Presentation: Pilonidal Abscess

Acute Pilonidal Abscess: an acute abscess, needs I&D

Chronic Abscess: an established pilonidal sinus cavity; chronically drains; fails to heal due to retained hair/foreign body

Recurrent Abscess: recurs after apparent complete healing previously

Treatment: I&D w/ incision parallel to the midline and at least 1 cm lateral to it (facilitates healing)

- not advised to excise during active inflammation
- antibiotics only if significant cellulitis
- any hair within 2 inches should be shaved

Initial Presentation: Draining Chronic Abscess**Shaving:**

- one study by Armstrong et al, however flawed
- showed shaving works
- current recs: shaving until complete healing

Midline Excision:

- remove only diseased tissue
- does not have to go to presacral fascia
- Kronborg et al: closure vs. open similar final outcomes, but closure groups healed in 15 days (vs 64 for open)
- antibiotic ointment to wound had no effect
- Primary closure: higher rate of wound complications

Unroofing and Secondary Healing:

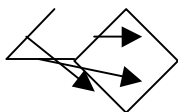
- decreases healing time from excision and leave open technique
- recurrence rate less than 13% reported

Bascom I: curettage and Pit excision:

- Generous vertical incision off midline (> 1cm)
- curette out without excising chronic fibrous wall
- undermine skin to chronic draining tracts/pits
- diamond excision of pits
- flap of skin sutured down
- shaving until healed
- No trial comparing this vs. other technique

Rhomboid (Limberg) Flap:

- works well for flap coverage of chronic wounds in the gluteal cleft that have failed to heal over a prolonged time.

**Karydakis Flap:**

- goal: remove tissue, and place wound out of midline
- Off center (> 1 cm) elliptical incision
 - studied 7,471 patients
 - 1% recurrence rates
 - 8.5% rate of infection
- no other studies using this technique

Bascom II (Cleft Lift):

- detaches the skin of the gluteal cleft from the underlying subQ tissue as a flap
- has not been duplicated to eval results

V-Y Plasty:

- Schoeller et al: 24 pts with advancement flaps
 - report no recurrences
 - 2 wound dehiscences

Z Plasty: another option

Myocutaneous Flaps: for most severe cases

Skin Grafting: no study published since 1983

- Guyuron ('83): 1.7% recurrence, 3.4% graft failure

HIDRADENITIS SUPPURATIVA

- involves apocrine sweat glands in perineum, axilla, groin

Incidence:

- AA > Caucasians
- M>F in perianal region
- Almost all after puberty and before age 40
- Smoking

Microbiology:

Staph epi (MC), E. Coli, Klebsiella, Proteus, Alpha Strep, anaerobes, diphtheroids.

Pathogenesis:

Obstruction of apocrine glands with keratin

Differential:

Does not affect rectum (apocrine glands only in lower third of anal canal)

- should not see sinus/fistula tracks to or from rectum
- should not penetrate the sphincter

Possible to have concomitant disease

50% increased cancer risk – can develop SCC

Treatment: Initial:

- I&D if abscess
- no abscess: antibiotics
- No evidence to support prophylactic abx

Treatment: Chronic:

- unless the skin is excised, at risk for recurrence
- excision w/ healing by secondary intention most widely used treatment
- only diseased tissue, wide excision not supported
- can be staged excision if widespread disease
- if near anal canal, stage it to prevent stricture

16 Perianal Dermatology and Pruritis Ani**DEFINITION:**

Pruritis Ani: itchy anus

Primary: idiopathic pruritis ani

Secondary: identifiable cause or a specific diagnosis

Macules: flat spots

Papules: elevated circumscribed solid lesions, raised spots

Vesicles: separations of the epidermis & dermis filled w/ fluid

Bulla: surface lesions w/ loss of continuity of the skin

Intertrigo: inflammation seen b/n 2 opposing skin surfaces (e.g. in obesity)

PHYSIOLOGIC CONSIDERATIONS:

Substances that produce itching: histamine, kallikrein, bradykinin, papain, trypsin

- topical anti-histamines only work for histamine
- so not always effective to stop itch

ETIOLOGY OF PRURITIS:**Fecal Contamination**

Study by Caplan on 27 men –

- fecal sample to arm skin vs control
- symptoms w/in 6 hours, relieved by washing skin
- suggests an irritant effect

Other findings (in other studies):

- coffee decreases anal resting pressure (leakage)
- anal inhibitory reflex more pronounced in many pruritis ani
- as many as half have poorly formed stool & multiple Bms

Viral Infection

No evidence of viral etiology, lesions easy to distinguish:

Herpes: pain rather than itching, macules → vesicles

Molluscum Conagiosum: popular lesions 2-5 mm, central umbilication, clustered

Fungal Infection:

Candida rarely, but in those with immunocompromise, DM,

...

Dermatophytes: *Trichophyton Rubrum*

- again rare (<5%)

Bacterial Infection – Erythrasma:

β-hemolytic strep, staph A, *Corynebacterium minutissimum* all implicated

C. Minutissimum probably in normal skin, but in moisture, diabetes and obesity may become infected with it

All patients with Erythrasma should have cure with erythromycin treatment

Psoriasis: in about 5-8% -- treatment with fluocinolone acetonide 0.025% (Synalar)

Lichen Sclerosus: chronic disease of unknown cause, almost always occurring in women

- white, atrophic, wrinkled lesions

- Biopsy is characteristic

- Rx: Clobetasol Propionate 0.05% (Temovate) for 6-8 weeks

- 4-5% risk of Squamous Cell CA formation → surveillance

Food: six common foods – coffee, tea, cola, beer, chocolate, ketchup. Total elimination will result in remission by two weeks. After 2-week period, foods can be re-introduced to thresholds that will cause symptoms.

Steroid Addiction: rebound phenomenon after withdrawal of steroids leading to their reinstitution and chronic use because symptoms always exacerbate after withdrawal.

- Potency and dosing should be tapered down

Contact Dermatitis: from trauma of wiping –

- Rx: Dilute white vinegar (15 ml in 8 ounces of water) and Burow's Solution (Domeboro) good for cleansing agents

Anal Tattooing:

Few numbers, last resort treatment

- 10 ml 1% methylene blue + 5 mL NS + 7.5 mL 0.25% bupivacaine w/ epi (1/200,000) + 7.5 mL 0.5% lidocaine
- perianal skin up to the dentate line injected

TREATMENT OF PRURITIS ANI

1. Specific directed treatment for diagnosis
2. Eliminate offending agent
3. Eliminate Scratching
4. Control Symptoms
5. Hygienic Measures (Dove soap, detachable shower head, hair dryer)
6. withdraw inappropriate steroids
7. Treat infection (silver sulfadiazine cream, clinda/gent topical, antifungal)
8. Protect skin (Zeasorb)
9. Correct any anal disease
10. Judicious use of appropriate steroids
11. Emphasize control of chronic condition
12. Reassess
13. Anal Tattooing in extreme cases

17 Sexually Transmitted DiseasesEtiologies:

- Anal Intercourse MC
- 2% of males (2-10% lifetime)
- 5-10% of females, more often unprotected

Anorectal Immunology:

With anal intercourse - breakdown of the mucous complex protecting the rectum

- abrades the mucous lining and delivers pathogens directly to the crypt and columnar cells -- allows easy entry
- may burrow into cell
- may proliferate on the cells
- may incorporate into cell DNA

Neisseria Gonorrhoea:

Gram negative diplococcus -- urethritis & cervicitis

- MC bacterial infxn of anorectum
- infect columnar cuboidal or noncolumnar epithelial lined cells - urethra, endocervix, rectum, pharynx
- frequently asymptomatic
- 50% males, 95% females
- main reservoir for persistent infections

Sx: non-specific proctitis, erythema, edema, friability, pus

Dx: culture on specific media (Thayer-Martin) incubated in CO₂ rich environment and gram stain

Rx: Ceftriaxone or Cipro/Levo

- 14% quinolone resistance in California/Hawaii

No follow up required, 100% efficacious treatment

- only follow if still symptomatic

Treat all for Chlamydia at same time

- no sex until treated, all partners within 60 days treat

Chlamydia/Lymphogranuloma Venereum

Px: obligate intracellular bacterium

- Different Serovars produce different infection
- Serovar D - K: proctitis & genital infxn's - less invasive and mild proctitis
- Serovar L1-L3: lymphogranuloma venereum - more invasive, cause ulcerations, abscess, strictures
- incubation 5d - 2wks

Lymphogranuloma V.: ulcerations/abscess and Lymphadenopathy of iliac, perirectal, inguinal & femoral

- large indurated matted nodes, similar to syphilis

Dx: cotton/Dacron swab w/ inert shaft

- rectal Gram stain showing PMN w/o visible gonococci is presumptive chlamydia if clinical picture fits
- tissue cultures low sensitivity, hard to transport

Rx:

- Non- LGV: Azithromycin 1g x1 or Doxy 100mg bid x 7d
- LGV: 21 days of treatment with either
- no sex until 7 days post treatment

Syphilis

Spirochete Treponema Pallidum - several stages:

- Primary - Chancre/Proctitis
- 2-10 wks s/p exposure
- small papules that eventually ulcerate, usually painful without exudates, single or multiple
- painless LAD
- lesions will usually heal
- Secondary - condyloma lata

- 4-10 weeks p primary if untreated, hematogenous spread
- non-specific symptoms -- fever, malaise, arthralgias,
- maculopapular rash on trunk and extremities
- *Condyloma Lata*: gray/whitish wart-like lesions that appear adjacent to the primary chancre; filled with spirochetes
- untreated will resolve w/in 3-12 weeks
- Tertiary

Dx:

- 1st or 2nd stage w/ Dark-field microscopic scrapings from chancres;
- direct fluorescent antibody test for T. Pallidum
- VDRL, RPR, serologic tests, but False Negative to 25%

Rx: Pen G 2.4 mil U IM x1 (1st and 2nd stage)

- recheck in 6 months w/ serolog to ensure treated
- if HIV+ 3 months and repeat
- check partners within:
 - stage 1: 3 months
 - stage 2: 6 months
 - stage 3: 1 year

Chancroid

ulcerating STD, G(-) facultative anaerobic bacillus H. Ducreyi

Px: contact through breaks of skin -- causes ulcers

Sx: infected tender papules - then pustules - then

- ulcerated and eroded, multiple and painful
- can drain from genitals to anal area
- unilateral painful inguinal LAD (M>F)
- facilitates HIV transmission and vice versa

Dx: gram stain & cx from base of ulcers

Rx: Azithromycin 1g x1 or Ceftriaxone 250 mg IM

Granuloma Inguinale (Donovanosis)

ulcerating infection by Calymmatobacterium Granulomatis

- AKA Donovanias Granulomatis

very rare in US

- does not require sexual contact

Sx: nontender, fleshy, beefy red ulcers - genitalia MC

Dx: routine cultures low sensitivity

Rx: Doxy 100 BID x1wk or Bactrim bid for 3 wks

Herpes Simplex Virus

HSV-1&2, EBV, Varicella, CMV

- asymptomatic HSV-1 common

Sx: Vesicles and ulceration, heal usually after 3wks

- HSV-2 proctitis via anal intercourse
- limited to distal 10 cm - diffuse friability
- tender inguinal LAD (50%)
- sacral radiculopathy - paresthesias/neuralgias, urinary retention, constipation, impotence

Dx: multinucleated giant cells w/ intranuclear inclusion bodies on Pap Smear/Tsank prep

Rx: supportive, sitz; Acyclovir x 10d decreases symptoms

Human Papilloma Virus

DNA papovirus

- 6 & 11: MC, low risk
- 16 & 18: greatest risk of dysplasia and anal CA

Sx: perianal involvement w/o receptive intercourse can happen

Dx: physical exam alone

- anoscopy, rarely above the dentate line

Rx: destruction of all gross disease w/ minimal morbidity

- HIV+, recurrent lesions, flat lesions or suspicious should all be sent to path
- recurrence rate 20-30%
- Podofilox or Imiquimod topical - however not approved for anal canal

Buschke-Loewenstein Lesion: WLE w/ 1 cm margin

Anal Cancer Development

HIV males at 38x risk v. general pop

Molluscum Contagiosum

poxvirus family benign papular condition of skin

- sexual and nonsexual contact

Px: incubation 1-6 months

Sx: flesh colored umbilicated papules

Dx: clinical grounds

Rx: curettage, bovie, cryotherapy

- Podophylotoxin and imiquimod (not FDA approved)

HIV and AIDS

may have worse healing if low CD4 counts

Anal Fissures should always be tested for underlying STD or pathology

Treat Fistula patients if AIDS like in Crohn's

Thrombosed hemorrhoids, treat like HIV- patients

- elective hemorrhoidectomy, up to debate

18 Benign Colon: Diverticular Disease**INCIDENCE**

- 5% by 40, 80% by 80
- 10-20% symptoms → 10-20% of those inpatient
- 10-50% of inpatient → surgery (<1% of all need surg)

PATHOPHYSIOLOGY

- High intraluminal pressures – 90 mmHg at peak (9x wnl)
- Herniation at *vasa recta brevia* – where blood vessels penetrate muscle to reach mucosa
- most b/n mesenteric & anti-mesentinea
- muscular layer does not herniated
- acquired or *pulsion* diverticula for most
- patients with diffuse diverticulosis, may be due to connective tissue abnormality

ETIOLOGY

- possible disturbance in cholinergic activity
- diverticular disease more cholinergic innervation than normal colon

EPIDEMIOLOGY

- Diet: high red meat & low fruit/veggies increase diverticulosis. Veggies & brown bread protective.
- fermentation of fibers – provides butyrate for colon
- Age/Sex: Pts <50 yo more often with chronic/recurrent diverticulitis
- men bleed more often, women bladder fistula more
- NSAIDS: increased rates of complications from diverticula via inhibition of COX → decreased Prostaglandin
- Immunocompromised: associated w/ increased risk – more likely from inability to prevent containment
- Opiates: increase intracolonic pressure, slow intestinal transit – both increase risk of complications
- Smoking: relative risk of complication: 3x, but new study refutes this
- Alcohol: may also have risk, but data refuted because alcoholics have worse diet habits, which may be cause

CLINICAL MANIFESTATION**Non-Inflammatory Diverticular Disease**

- symptoms without associated inflammation

Acute Diverticulitis:

Hinchey – for complicated acute diverticulitis:

- Stage I: localized abscess
- Stage II: confined pelvic abscess
- Stage III: purulent peritonitis
- Stage IV: fecal peritonitis

Chronic Diverticulitis:

- remain symptomatic despite standard treatment.
- *Atypical*: if never develop systemic signs
- usually associated with a phlegmon

Complex Diverticular Disease:

- chronic + fistula/stricture/obstruction

NATURAL HISTORY

- increasing risk w/ age & no diet modifications
- progression from one segment of bowel to next does not typically occur – unusual for complications to

develop in the proximal colon after Rsnx of diseased sigmoid.

- est. 10% will recur after first outpatient episode
- est. 70% will recur after 2 inpatient treatments

PRESENTING SYMPTOMS

- LLQ abd pain
- no prodromal epigastric pain, rare n/v
- bleeding atypical, if so ensure no other diagnosis (CA)

COMPLICATIONS:

Bleeding: not a feature of diverticulitis

Perforation: focal to diffuse

Abscess: consider perc drainage

Fistula: bladder MC; if clinical hx c/w it, imaging w/u not a must

Stricture/Obstruction: caution w/ use of stents; may need diversion due to size mismatch

Ureteral Obstruction: most often will resolve with treatment of diverticulosis

Phlegmon: better to treat to resolution before surgery

Saint's Triad: diverticulosis, cholelithiasis, hiatal hernia – unknown clinical significant

DIAGNOSTIC TESTS

Endoscopy: caution in acute phase; unless really indicated, delay until inflammation resolved

- if acute phase discovered during elective scope, antibiotics are not necessary

AXR: to rule out pneumoperitoneum

Contrast Studies: to eval stricture/obstruction, fistulas

CT Scan: documents –itis phase.

U/S: not really used, some research into its use

MRI: correlates with CT findings, no radiation

DIFFERENTIAL DIAGNOSIS

IBS: know Rome II criteria to distinguish:

Rome II: pain that is at least 2 of 3 below in last 12 months

1. relieved with defecation
2. onset associated with frequency of BMs
3. Onset associate with form of stool

Red Flags not associated with IBS: disturbed sleep from the pain, blood, weight loss, fever, abnormal exam

Colon Neoplasia: scope the patient

IBD: Crohn's may mimic; recurrent diverticulitis after

previous resection should make you consider Crohn's

Polycystic Kidney Disease: very high association with

sigmoid diverticulosis – some transplant centers request prophylactic sigmoid colectomies before transplant

UNCOMMON PRESENTATIONS

Young Patient: more likely to have complicated recurrence of initial CT demonstrates significant disease

Rectal Diverticula: rare, typically true, usually solitary; most can be managed conservatively

Cecal/Right Sided: more common in far east; present younger w/ R sided; cecal diverticula are *true* ticks;

- Four Grades: I – inflamed tick; II – inflamed cecum; III – localized abscess; IV – rupture/perforation
- often confused as appy, and taken to OR; always take out appendix, even if only thing you do, to prevent confusion in the future.
- procedure of choice is appy and close, or appy + diverticulectomy vs. right hemi (if not identifiable disease or concerned for cancer)

Giant Colonic Diverticulum:

- sigmoid; pseudo-tic w/ inflammatory (not mucosal) wall
- unknown mech; as large as 30-40 cm
- large gas filled cavity on plain film
- Rx: Resection of involved colon

Transverse Colon Diverticular Disease:

- very rare
- females, younger age
- more often resected because difficult diagnosis

TREATMENT

- Diet: 20-30 g of fiber daily
- no data to restrict eating seeds

Acute Diverticulitis: outpatient, antibiotics, low residue/clear diet

- gram negative and anaerobes; E. Coli & Streptococcus, Bacteroides, Peptostrepto, Clostridium, Fusobacterium
- Inpatient: make NPO initially, then advance PO

SURGICAL MANAGEMENT

- *Hartmann's*: oversewing rectal remnant
- *Mikulicz*: mucous fistula of rectum
- most argue b/n 1 vs. 2 stage op; 3 stage historical

Abscess: that can't be drained – consider Hartmann's

- 35-45% of people will never have second stage

Complications: low pelvic anastomotic leak rate: 2-5%

Indications: current ASCRS guidelines:

- elective Rsn after 1-2 well-documented episodes
- after 1 if it was a severe attack (abscess, air)

Mgmt of Fistula:

- Bladder: drain for 5-7 days alone
- Vagine: no treatment
- Cutaneous: will close spontaneously

Technique:

- remove all thickened bowel, NOT all bowel with tics
- ALL sigmoid should be taken out
- retained sigmoid: MC reason for recurrence

19 Colonic VolvulusCECAL VOLVULUS

Incidence: most common in young females (53 yo)

Pathogenesis:

Cecal Volvulus: axial torsion of ileum and colon

- forms closed loop and SBO together

Cecal Bascule: cecum folds anteriorly cephalad, not twist

- Association with prior surgery; considered risk factor
- congenital lack of fixation also postulated

Symptoms:

- small bowel obstruction
- difficult to diagnose

Diagnosis:

- Coffee bean deformity towards LUQ
- contrast: bird's beak

Treatment: celiotomy

Cecopexy: elevate lateral peritoneal flap along entire length of ascending colon, suture flap to anterior surface of the serosa of colonic wall – places it partially retroperitoneal (12-14% recur)

Cecostomy: after removal of the tube, spontaneous closure is common (12-14% recurrence)

- can combine the above 2

Resection: likely 0% recurrence

TRANSVERSE COLON VOLVULUS

Incidence: very rare – 1-4% of all volvuli

Path/Et: constipation, laxative use; congenital disease

Clinical Presentation: large bowel obstruction; chronic subacute process or fulminant course

- plain film rarely diagnostic
- contrast enema: bird's beak distal T-Colon

Treatment: segmental transverse colectomy or extended right hemi

SPLENIC FLEXURE VOLVULUS

Incidence: rarest form, <50 case reports (young women)

Path/Et: 3 ligaments important in normal flexure:

gastrocolic, splenicocolic, phrenocolic; congenital lack of or disruption in these leads to it; 2/3 had prior surgery

Clinical Presentation: large bowel obstruction; chronic subacute process or fulminant course

- plain film: significant air in colon up to splenic flexure; two air fluid levels in cecum & T-Colon; empty descending colon; crescentic gas shadow in LUQ
- contrast enema: bird's beak at Splenic Flexure

Treatment: segmental colectomy or extended left hemi

- many will have very dilated colon, so may have to do ileosigmoid or ileorectal anastomosis

SIGMOID VOLVULUS

Incidence: MC volvulus, but only 10% of all LBOs (men)

Path/Et: elongated colon, redundancy;

- in US: elderly, institutionalized male, psychotropic med

- *Shrinking MesoSigmoiditis:* scarring patches and bands from previous volvulus that resolved
- once 360 degrees – closed loop obstruction
- 3 patterns of necrosis:
 1. at neck of volvulus
 2. any location in closed loop
 3. proximal descending colon due to retrograde mesenteric thrombosis

Clinical Presentation: male, constipated, nursing home, on psychotropic meds

- 40-60% will have had symptoms in past
- significant distention usually
- plain film (diagnostic in 70%): *bent inner tube sign*
- contrast enema: bird's beak

Treatment:

- emergent sigmoid detorsion – rigid proctosig, flex sig, colonoscopy, blind rectal tube, barium contrast – successful in 70-80%
- 50% will already have gangrene, some recommend just go straight to laparotomy; others recommend if detorsing, can do so if not a blind technique
- detorsing nonviable bowel leads to higher rate of perf
- rectal tube should be placed during detorsion and fixed in place
- patient resuscitated, can do full colonoscopy to eval for no malignancy or other disease
- 25% will recur without surgery (some report upto 80%)
- can then do *sigmoid resection* – standard of care

Mesosigmoidolasty: incising the elongated sigmoid mesentery vertically, reclosed transversely; shortens and broadens the mesentery. Most report recurrence <2% (one 28%)

- if go emergently to OR and dead bowel found – DO NOT detorse first. First step is *Vascular control*. Prevent spread of inflammatory toxins

Mortality rates higher without pre-op detorsion and resuscitation: 45% vs. 10%

ILEOSIGMOID KNOTTING – COMPOUND VOLVULUS

Incidence: rare form, men almost all less than 50 yo

Path/Et: associated with single large meal with lots of fluid

- ileum around sigmoid or vice-versa

Clinical Presentation: usually first attack

- fulminant course common, present in shock and intra-abdominal catastrophe
- intestinal gangrene on exploration in 70-100%

Treatment: if nonviable, vascular control before detorsion

- sigmoid segmental to prevent retrograde mesenteric thrombosis
- mortality: 40-50% if dead bowel, 10-30% if viable

20 Lower Gastrointestinal Hemorrhage

Diverticular Disease: Approximately 50% of the population by age 60 years has evidence of diverticulosis

Angiodysplasia: thin-walled arteriovenous communications located within the submucosa and mucosa of the intestine

- loss of vascular integrity related to loss of TGF β signaling cascade or from a deficiency in mucosal type IV collagen
- uncommon before age 60, increase with age, associated w/ Aortic stenosis, CRF, von Willebrand's Dz
- Angiography gold standard to diagnose
 - early venous filling and *tufts**
- On scope: cherry red lesion, flat, "fern-like", > 2mm
- originally thought to be only on right side, now known to be bilateral

Occult Hemorrhage: may need capsule endoscopy

ASSESSMENT, RESUSC, AND STABILIZATION

1. gastric lavage
2. anorectal exam, proctoscopy
3. then either: scope, angio or bleeding scan
 - Major/Ongoing*: angiography/surgery
 - Minor, self-limited*: colonoscopy
 - Major, self-limited*: unclear, up for debate

Radionuclide Scanning:

- detects rates 0.1-0.5 mL/min
- cannot reliably localize site of hemorrhage
- sulfur colloid or ^{99m}Tc pertechnetate-tagged rbc
- if demonstrates:
 - *Immediately Pos. Blush (1st 2 minutes)*: highly predictive (60%) of positive angio, 24% need surgery
 - *No blush*: predicts negative angio (93%), 7% surgery

Angio: needs bleeding rate 1 mL/min

- can give vasopressin 0.2 – 0.4 U/min to site

Operation:

- Consider if > 6-7 units of blood
 - < 10 units of blood: 7% mortality rate
 - > 10 units of blood: 27% mortality rate
- Make sure to palpate entire intestinal system (small, stomach) to ensure no masses
- if no source found, subtotal/total colectomy
 - anastomosis pending how stable patient is

21 Endometriosis

- cyclical pain/bleeding which coincides with menses

Etiology: unknown cause, familial component – 2 theories

(1) *Coelomic Metaplasia*: coelomic epithelium will undergo metaplastic changes and transform into endometrial tissue

(2) *Retrograde Menstruation*: retrograde menstruation through fallopian tubes and into the peritoneal cavity – most likely pathway

Clinical Manifestations:

Common	Less Common	Rare
Ovaries 60-70%	Appendix 2%	Diaphragm
Uterosacral Ligs 30-65%	Ureter 1-2%	Inguinal Canal
Cul-de-sac 25%	TI 1%	Liver
Uterus 4-20%	Bladder <1%	Spleen
Rectosig Colon 3-10%	Scars <1%	Kidney

Symptoms: MC – menstrual irregularities, pelvic pain, infertility, or may be asymptomatic – spectrum between this

- pain most intense just before menstruation and lasts for the duration of menstruation

Pelvic Pain and Dysmenorrhea

- pain MC symptom (80%): dysmenorrheal, dyspareunia, or chronic noncyclic pelvic pain

- associated: back pain, dyschezia, levator M. spasm

- total lesion volume correlates with pain

- *Dyspareunia*: deep pelvic pain w/ vaginal penetration

- usually in advanced endometriosis

- indicative of degree of fixation of the pelvic organs

- *Chronic Non-Cyclical Pain*: pain > 6 mo, intermittent or continuous;

Infertility:

- unclear relationship/cause

- may be to adhesion formation in the pelvis

- may benefit from surgical treatment

Intestinal Symptoms:

- bowel involved in 12-37% - symptomatic variable

- 70% will be rectosigmoid

- *Rectosigmoid Dz*: change in BM, diarrhea, decreased caliber, tenesmus, rare bleeding around menses

- can cause perforation

- if asymptomatic – benign natural history- *don't resect asymptomatic patient*

Malignant Transformation

- not common, happen at younger age (40s)

- Signs of CA: > 10cm, cyst rupture, or change in pain

- rectosigmoid most common area of CA origin ones

- Most common symptom: rectal bleeding

- risk factor: prolonged unopposed estrogen exposure

- Endometrial CA MC type; 60% survival at 5 years

- Histologically: arise from the colon, not invading it

DIAGNOSIS

Physical Exam:

- may be normal

- bimanual exam: nodularity/induration in the uterosacral ligaments or cul-de-sac of Douglas

- possible ovarian mass

- cyclical pain/bleeding from any location that coincides with menses should be worked up for endometriosis

Laboratory Evaluation:

- CA-125: low sensitivity, low specificity

- better for surveillance than diagnosis

Endoscopy:

- usually normal since lesions are on outside of bowe

- unless advanced disease → luminal narrowing

Imaging Techniques:

- TransVag U/S: good to detect ovarian implants only

- TranRectal U/S: may have use for pouch of douglas

- BE: extracolonic mass

- CT: higher sensitivity, lower specificity

- MRI: more sensitive than CT

Laparoscopy:

- only definitive way, can be used to diagnose those when other tests have failed

- does not have to be timed to menses

- Examine all small bowel, appendix, pouch of douglas, uterosacral ligaments, both ovaries, sigmoid colon, ureters

TREATMENT:

Medical Management:

- treat symptoms – pelvic pain

- neoadjuvant treatment 3-6 mo → decrease burden

- 3 month trial of danazol or GnRH-a to determine cause

- if endometriosis, most no pain w/in a month

- can be used as bridge, can still get pregnant

- will not cure disease, will relapse once stopped

- OCPs: work, but can't get pregnant. Good if no desire.

- *Danazol*: older drug, lower peripheral estrogen & prog levels; 5% get side effects of menopause type

symptoms, hirsutism, acne, weight gain; do not use in patients with liver disease or atherosclerosis

- *GnRH-a*: suppresses release of FSH & LH; same efficacy as danazol, but less SEs. Menopause like symptoms, bone loss.

Surgical Management:

- Goal: completely excise/ablate endometrial implants, preserve ovarian function, optimize fertility

- implants can be deeper in tissue than can always tell – be careful of iatrogenic injury to other organs

- ureteral stents advised in all of these

Rectovaginal Endometriosis:

- most lesions can be removed w/o entering mucosa

- may need anterior resection vs. wedge (if < 3cm lesion)

- margins: grossly normal bowel

Appendix: appendectomy

Small Bowel: wedge or resection

22 Colon and Rectal Trauma and Rectal Foreign**Bodies**COLON INJURIES

Intraoperative Paracolic Hematoma:

- penetrating trauma: explored & colon evaluated
- blunt trauma: no routine exploration

AAST Colon Injury Score

- Grade I: contusion/hematoma w/o devasc or partial thickness lac
- Grade II: Lac <50% circumference
- Grade III: Lac >50% circumference
- Grade IV: transection
- Grade V: Transection w/ segmental tissue loss
- Class I evidence for primary repair in all Grade I & II
- Rates of complications:
 - Diversion: 21.7%
 - Primary Repair: 13.1%
- THM –primary anastomosis in most instances.

Risk Factors for Abdominal Complications:

- overall rate in colon injury: 20%

Left vs. Right Colon: old theory left > right, but there is no evidence to support this. All evidence shows they heal equally

Associated Abdominal Injuries: current class I & II evidence supports primary repair or resection and anastomosis in patients with severe or multiple associated abdominal injuries

Shock: class I & II evidence that is not a risk factor nor a contraindication to primary repair

Massive Blood Transfusion: method of colon repair not associated with abdominal sepsis – can do primary

Injury Severity Score: ISS > 15 not associated as RF

Fecal Contamination: high risk for abdominal sepsis but should not affect the anastomosis – still recommend primary repair

Specific Organ Injuries: not a single organ associated with higher rate of leak – no organ should influence decision to do primary repair

Time from Injury to Operation: not identified as risk factor

Retained Missile: can be left in place, not a risk factor for problems later.

Temporary Abdominal Wall Closure: would advocate no ostomy since makes wound mgmt harder

Anastomotic Leaks:

- overall 2-3% leak rate
- colocolostomies 9 (13%) > ileocolostomies (4%)
- enterocutaneous fecal fistulas most can be managed non-op and will heal spontaneously after perc drainage
- re-exploration should only be reserved for those with generalized peritonitis or failed perc drainage

Technique of Colon Repair:

- GSW: debride edges first, primary repair
- destructive injury: resect to normal colon
- identical complication rate b/n stapled & hand-sewn

- rec fibrin glue and omental wrap but no evidence

RECTAL INJURIES

- Eval with DRE and Rigid Procto

AAST Rectal Injury Score

- Grade I: contusion/hematoma w/o devasc or partial thickness lac
- Grade II: Lac <50% circumference
- Grade III: Lac >50% circumference
- Grade IV: full thickness into perineum
- Grade V: devascularized

Intraperitoneal Injury: no evidence to say what to do – for now treat like left colon – repair it.

Extraperitoneal Injury:

- 1) Fecal Diversion
- 2) ~~presacral diversion~~ – no evidence to support it
- 3) ~~distal rectal washout~~ – no evidence to support
- 4) repair of injury when possible

Associated Injuries: 77% of rectal injuries will have

- 30-40% bladder involved
- try to interpose omentum – 24% of patients develop rectovesicle fistula

WOUND MANAGEMENT

- 11% wound infection rate
- recommend delayed closure at 3-5 days

Antibiotic Coverage:

- no evidence for use over 24 hours
- recommended unasyn or zosyn

Ostomy Complications:

- ~15% complication rate during takedown
- can close sooner than 3 months, some do same admission

Rectal Foreign Bodies:

- operative intervention most likely if in sigmoid

23 Colorectal CA: Epidemiology, Etiology & GeneticsEPIDEMIOLOGY

In US: 3rd MC CA, 2nd MC cause of CA death

- 630,000 deaths annually worldwide, ~60,000 in US
- 40% higher risk in men
- 90% in those > 50 yo

ETIOLOGYDietary Fat:

- saturate animal fat carcinogenic
- no association for total fat and carcinogenesis
- low evidence, red meat more associated

Red Meat:

- stimulates N-nitroso compound formation
- well done meat more implicated
- processed meats w/ daily of 100 g red meat highest association
- may be because consuming less of protective diet

Fruit and Vegetable Intake:

- antioxidants – carotenoid and ascorbate
- protective effect
- some studies show no difference
- some show only vegetables

Fiber:

- seems protective role, but may be correlation with other healthy life habits
- not enough data

Calcium: protectiveFolate: protectiveAlcohol: high levels associated w/ carcinoma

ASA and NSAIDs: may be protective, but not considered to be cost effective given side effects and low quality data

Hormone Replacement Therapy: protective; but due to adverse events, not to be used as a primary CRC preventative measure

Obesity: increased risk CRC;

Physical Activity: more is protective;

Smoking: heavy smoking associated w/ increased risk

- >20 cigarettes per day for long periods of time

Cholecystectomy: increased bile flow may have association with CRC; evidence poor

Inflammatory Bowel Disease: increased risk after 10 years

Family History: increased risk

- 2.25 RR w/ one 1st degree relative
- 4.25 RR w/ >1 1st degree relative

Radiation: small association with rectal mucinous tumors; most will not develop cancer

Ureterosigmoidostomy: associated with increased risk in the area of the anastomoses;

- up to 24% of these patients develop CRC by average of 26 years
- risk remains after conversion
- need regular flex sig surveillance

Acromegaly: associated w/ increased CRC risk

- RR unknown, 2.6 – 18.3

MOLECULAR BASIS

Carcinogenesis – Six identified steps:

- (1) Self-Sufficiency in Growth signals – proliferate autonomously
- (2) Insensitivity to antigrowth Signals –
- (3) Evading Apoptosis –
- (4) Limitless Replicative Potential
- (5) Sustained angiogenesis –
- (6) Develop ability to invade and metastasize – must lose cell adherence properties and ability to survive in a new environment

Mutations genes:

Oncogenes: abnormal gain of function

- *ras*: most frequent in CRC (50%) – *K-ras* on 12p is proto-oncogene that becomes mutated
- *c-myc* and *c-erbB2* also in CRC

Tumor Suppressor Genes: inhibit growth or promote apoptosis

- two hit theory.
- *APC* – long arm of 5q in 75% of CRC – gatekeeper gene of CRC; regulated *Wnt* (*wingless signaling pathway*) – modulates *beta-catenin*.
- *I1307K* mutation on *APC* – Ashk-Jews → CRC
- *p53*: short arm 17p – slows cell cycle to allow for DNA repair: If not feasible, induces apoptosis.
- *DCC* (*Deleted in CRC*) – long arm of 18q – important in cell-cell adhesion; in most CRCs; enhances CRC metastatic potential.

Mismatch Repair System: to find errors in coding

- microsatellite instability: regions of DNA don't code for protein; most susceptible to MMR
- labs test for five MSIs – if >1 MSI = MSI-H (high), if 1 = MSI-L (low), if non = MSI-stable
- 15% CRC has MSI – MSI-H – R-sided, mucinous, tumor infiltrating lymphocytes
- *MLH1*, *MSH2*: MC (>90%) of MSIs in HNPCC, *MSH6* in 5-10%, the rest more rare

MYH Gene: DNA repair gene active for A-G Mismatches; found to be responsible for some APC mutation-negative FAP.

Chromosomal Instability Pathway: thought to be pathway to formation of sporadic CRC.

- MSI-H is different pathway

24 Screening for Colorectal Neoplasms

Colon & Rectal CA 2nd leading CA death in US

Gatekeeper of colorectal Neoplasia: Adenomatous polyposis coli gene

Average Risk (75%)

Do not fit any of higher risk categories

Screening Recs begin at age 50:

- yearly FOBT
- Flex sig Q5yrs
- FOBT + flex sig Q5yrs
- Air Contrast BE Q5-10 yrs
- Colonoscopy Q10yrs

FOBT – low sensitivity, so really shouldn't be used alone

- has poor compliance
- sample three bowel movements while not eating red meat, ASA, NSAIDS, turnips, melons, salmon, sardines, horseradish or Vitamin C for 2 days.

Flex Sig: if find a polyp, do full colonoscopy - ~30% will have another proximal lesion

Air Contrast BE:

- < 1cm: 50-80% sensitivity
- > 1 cm: 70-90% sens
- Stage I and II: 50-80%

CT Colonography:

- Needs good oral prep
- rectal catheter with air insufflation used
- any positive findings need scope
- Initial studies show not as sensitive, but evolving

Personal History of Adenomatous Polyps or AdenoCA

All recommend colonoscopy

Initial post-resection scope: 1 year, followed every 3-5 years thereafter

- looking for metachronous disease

Family History of ColoCA or Adenomatous Polyps

If 1st degree relative – begin at age 40, or 10 years before the age at diagnosis of relative

If 2nd degree relative w/ CA or relative with polyps over age 60 – consider them average risk

Hereditary Nonpolyposis Colorectal Cancer

75% will have disease by age 65

Autosomal Dominant – mutations in mismatch repair genes; microsatellite instability common

Most tumors proximal to splenic flexure by age 40-50

- still get adenomatous polyps, despite the name
- tendency for multiple cancers
- at risk for other cancers, ovary and uterus highest

Amsterdam Criteria:

- colorectal CA in 3 or more Family members, 2 generations affected, at least one a 1st degree relative, at least 1 before age 50

Screening: start age 20-25, repeat Q1-3 years

Referral for genetic counseling

Regardless of testing (only 30-50% sensitive) needs scoping if meets criteria

Familial Adenomatous Polyposis

Autosomal dominant defect in adenomatous polyposis coli gene

100% cancer by age 40

Extracolonic tumors: duodenal adenomas, desmoids

Start colonoscopy at puberty

- flex sig then repeated Q1-2 years
- screening EGD for duodenal adenomas

Genetic testing: if shows proband with a positive truncated protein assay, relative that test negative can be screened as average risk individuals

Inflammatory Bowel Disease

UC patients with increased CA risk

- 7-8 yrs if pancolitis
- 12-15 yrs if left sided only

Crohn's colitis risk less established, suspected

Screening: Q1-2 years scope with multiple biopsies starting 7-8 yrs after diagnosis.

25 Polyps

Polyp: macroscopically visible lesion or mass projecting from an epithelial surface

ADENOMA

- a benign neoplasm of epithelium
- dysplastic and pre-malignant

Clinical Presentation

- most clinically silent, found during screening
- if large, may cause bleeding
- colonoscopy most accurate test for adenoma
 - BE FN rate to 52%, FP rate 14%
- CT colonoscopy 90% sensitive if >1 cm

Pathology

- rate of synchronous if one adenoma found: 40%

3 histologic subtypes

1. Tubular: >80% tubules dysplastic
2. Villous: >80% of villous fronds
3. Tubulovillous: 20-80% of each

Dominant risk factor for invasive CA: polyp size and villous histology

Pseudoinvasion: dysplastic epithelium becomes misplaced within the submucosa of a polyp & mimics invasive CA

- retains lamina propria, lacks other morphologic malignant features, presence of hemosiderin (sign of ischemia – thought to be cause)

Differing levels of dysplasia:

- *Mild*: tubules lined from top to bottom by epithelium similar to normal; nuclei enlarged, hyperchromatic; architecture normal
- *Moderate*: cellular polarity less preserved; nuclear stratification; glands more crowded
- *Severe*: large vesicular nuclei; irregular nucleoli; scalloped nuclear membranes; increased nuclear to cytoplasmic ratios; nuclear polarity disrupted; structural abnormalities

Epidemiology

Age 50: 24-47% rate of adenoma, increases with age

- family history increases risk of adenoma

Miss rates: >1 cm 5%; 6-9mm: 10%; <6 mm 30%

Adenoma-carcinoma Sequence

Lifetime risk of colorectal CA 6% by age 85

2-3 yrs for <5 mm adenoma to become 1 cm

2-5 yrs for 1 cm adenoma to become CA

> 1 cm lesion – 3%, 8%, 24% risk CA at 5,10,20 yrs

- all based off of model projections

Risk of CA conversion by type and size – (yearly)

- > 1 cm: 3%
- Villous: 17%
- high-grade dysplasia: 37%
- no invasive CA found in polyps <6 mm

Molecular sequence: APC gene deactivated in epithelial cell; other mutations in K-ras, DCC, p53

Management

- If see a polyp, important to see all the way to cecum

- majority, snare polypectomy

Rectal Adenomas

Consider TEM for excision

- if too proximal, consider anterior resection
- if not cancer and too distal, may need mucosectomy and hand-sewn coloanal anastomosis

Surveillance

- after polypectomy of large or multiple adenoma – cancer risk increased 3-5 fold
- first repeat colonoscopy at 3 years after polyp removal
- if low risk (3 or less all < 1 cm, no family hx) do at 5 yrs
- if first follow up negative, second at 5 years
- large sessile > 3cm, or piecemeal ones: 3-6 month for one year, and then at 6-12 months in second year, and then yearly up to year 5

The Malignant Polyp

Haggitt's Classification: Levels:

- 0: non-invasive (severe dysplasia)
- 1: cancer through muscularis mucosa
- 2: CA into neck of pedunculated
- 3: CA into stalk of pedunculated
- 4: cancer into submucosa – all sessile considered 4
- Risk of lymph node mets:
 - Levels 1-3: 1%
 - Level 4: 12-25%
- LVI, poor differentiation, microacinar structure, SM3 invasion into lower third of submucosa

Clear Margin for polypectomy: 2 mm

- piecemeal resections should be treated as positive margins even if “complete”
- anything high risk, do full oncologic resection

SPECIFIC ADENOMAS- NEOPLASTICFlat and depressed adenomas - neoplastic

Not elevated above the mucosa, not “true polyps” – best identified with chromoendoscopy

- high rate of associated cancer
- if detected, all should be removed

Serrated Adenomas - neoplastic

Has serrated crypts that are longer and broader than in hyperplastic polyps. Different than hyperplastic.

- same risks as regular adenoma, but different pathway
- may be related to MMR gene, shows e/o MSI

NONNEOPLASTIC POLYPSHyperplastic Polyps:

- failure of programmed cell death. Normal maturation, but more; most 3-5 mm in size
- Histo: Mature goblet cells (adenoma reduced goblets)
- ratio of 1:1 in incidence of <6 mm lesions
- not associated with increased risk of CA adenomas
- starlike pit pattern when stained with indigo carmine

- linked with MSI, so if have many (>30) than at risk for CA

Hamartomas: round, pink, smooth; dilated mucus-filled cystic spaces; polypectomy is snare. Non familial forms should be less than 3

Inflammatory Polyps: associated with colitis (UC)

- a remnant or island of normal or minimally inflamed mucosa;
- not associated with CA
- treat underlying disease

Lymphoid Polyps:

- benign enlargements of lymphoid follicles
- usually multiple;
- Criteria to define:
 - lymphoid tissue w/in mucosa/submucosa
 - no invasion of fascia propria
 - at least 2 germinal centers identified
 - if can't see muscle coat & <2 germinal centers – can't call it lymphoid polyp

26 Polyposis SyndromesFAMILIAL ADENOMATOUS POLYPOSIS

Autosomal Dominant – mutation in APC gene

Polyposis Registries

- provide counseling, support for FAP families
- assist with post op and surveillance

Features of FAP

Large Bowel: >100 adenomatous polyps; usually by teens, cancer by age 40; 25% due to new mutation

Extracolonic Manifestations: duodenal CA and desmoids as new major source of morbidity, others:

- Congenital Hypertrophy of retinal pigment epithelium

Genetics

The APC Gene: large gene on 5q21

- mutation of APC one of initial events, truncating APC product

The APC Protein: APC mRNA in higher levels in normal colonic mucosa; highest when cell replication done

Genotyp-phenotype Correlation in FAP: different codons associated with differing prognosis and age of onset

MYH Polyposis: autosomal recessive FAP

- mutation along MutY homolog (MYH) gene
- duodenal adenomas also, but not desmoids
- consider of no mode of inheritance found

Clinical Variants of FAP

Attenuated FAP: <100 polyps at 34-44 yrs

- still have APC mutation, and get extracolonic manifestations
- most polyps right colon
- clinical picture similar to HNPCC

Gardner's Syndrome: FAP, epidermoid cysts, osteomas, fibromas (term is considered obsolete now, since the extracolonic manifestations part of normal FAP)

Turcot's Syndrome: polyposis with CNS tumors

- MC: cerebellar meduloblastoma

Diagnosis:

Genetic Testing: 80% sensitivity, if positive, at risk family checked, between ages 12-15

Clinical Surveillance: scopes starting at 12-14 yrs of age

- if start with flex sigs, COYs by age 20

Mgmt of Large Bowel

Timing of Prophylactic Surgery:

- invasive CA rare under 18 yrs of age
- plan surgery b/n ages 16-20 for most

Choice of Operation:

- Proctocolectomy with End Ileostomy
- Colectomy with IRA
 - 12-29% risk of CA in rectum w/in 20-25 yrs
 - do NOT do if 1309 mutation or severe polyposis
- Proctocolectomy with IPAA
 - mucosectomy really only indicated in those with severe low rectal polyposis
 - 53% develop polyps in pouches – unknown significance at this point

- author recommends IRA if no 1309 or severe polyposis

Post-Operative Surveillance

- IRA: rescope Q6-12 months; remove all polyps >5mm
 - if severe dysplasia – completion proctectomy
- IPAA: annual scope, w/ good DRE

Chemoprevention:

- Sulindac, Celecoxib: reduced the # & size of adenomas
 - not a treatment to avoid cancer

Upper Gastrointestinal Polyposis

- Increase in Gastric CA polyps in Asia but not West
- 95% of FAP have duodenal adenomas
 - occur about 15 yrs later than large bowel polyps
- Everywhere but most just distal to ampulla of Vater
- 5% develop into CA at average age of 50

Surveillance of Duo:

- prognosis very poor for the few that progress
- **Spigelman Staging:** stratifies severity of duo polyposis
 - Stage II or III: 2% risk CA at 10 years; Stage IV: 36%
- upper EGD scopes starting at age 25

Management:

- very high recurrence rate, Whipple only curative treatment available

Desmoid Disease

- locally invasive, non-metastasizing clonal proliferations of myofibroblasts; 10-50% mortality
- develop in 10-15% FAP patients, ~30 yrs of age, or 2-3 yrs after surgery

Clinical Features:

- may encase small bowel vessel if in mesentery → ischemia/perforation
- 10% resolve spontaneously; 10% rapid growth, the rest cyclic

Management:

- when vessels involved, high periop mortality rate
- ureteric obstruction: best mgmt is stents
- Sulindac + Tamoxifen/Toremifene

Algorithm:

1. Sulindac 150-200 mg Bid
2. add Tamoxifen 80-120 mg Qd (if progresses)
3. consider chemo if continues to grow

PEUTZ-JEGHERS SYNDROME

- perioral, buccal, and sometimes genital melanin & GI hamartomas
- appears in childhood, fades in late 20s
- polyps mostly in SB, but also Stomach, colon & rectum
- hamartomas have branching morphology w/ smooth M.

Inheritance: autosomal dominant, high penetrance;

- mutation LKB1 (STK11)* on chrom 19p13.3
- encodes a serinethreonine kinase of unknown fxn

Polyp related complications: anemia from large polyps, or intussusceptions

Risk of CA: 50% cancer by age 57, however multifactorial, 20% colorectal, 5% gastric, 30% pancreatic, ...

GI Surveillance: Q3-4 months EGD & COY with SBFTs

- annual CBC to check Hgb
- polyp >1.5 cm warrants surgery for removal

Laparotomy in PJ syndrome: at largest polyp, enterotomy made and endoscopy through entire small bowel. All polyps removed w/ snare/forceps and retrieved

Extraintestinal Surveillance: testicular, cervical and breast screening; regular pancreatic screening not shown to be efficacious

Cronkhite-Canada Syndrome

- rare, adult onset, not inherited
- GI hamartomas
- Ectodermal Abnormalities: alopecia, onychodystrophy, hyperpigmentation of skin/face/eyelids
- Gastric mucosa like Menetrier's
- mal-absorption, hypokalemia, protein loss, tetany
- pathogenesis unknown
- supportive mgmt

JUVENILE POLYPOSIS

- multiple (3-5) JPs in large bowel, 50% also stomach
- only need 3-5, but most get 50-200
- hamartomas lacking smooth muscle, poor attachment, and can detach and be defecated, avg age 9
- 50% develop dysplasia and then cancer
- solitary JP – in 2%, no malignant potential
- 10-20% of patients: macrocephaly, MR, cleft lip, CHD, GU malforms, malrotations

Genetics: heterogeneous, 3 genes implicated.

- SMAD4 on 18q21
- BMPR1A on 10q22
- PTEN gene

Cancer risk mgmt: 30-50% risk colon CA, 10-20% upper GI

- 1st degree relatives: Annual COY starting at age 12
- if can't do with scopes (removal) colectomy w/ IRA or TPC w/ IPAA
- no evidence yet for prophylactic colectomy
- upper EGD surveillance starting at age 25

Cowden Syndrome: autosomal dominant;

- mutation in PTEN gene – encodes tyrosine phosphatase involved in inhibiting cell growth
- Sx: macrocephaly, trichilemmomas, neoplasms of thyroid, breast, uterus, skin
- hamartomas throughout GI, including mouth – results in nodular appearance of buccal mucosa

Bannayan-Riley-Ruvalcaba Syndrome:

- pigmented penile macules, macrocephaly, MR, lipomatosis, hemangiomas
- PTEN mutations
- colorectal CA risk not clear.

Metaplastic (Hyperplastic) Polyps:

- 40% will have by age 50
- unclear significance
- known microsatellite instability
- considered risk for CA increases w/ increased number of them in colon

27 Colon Cancer Evaluation and Staging

3rd most common cancer, 38% die from it

Clinical presentation:

- MC: abdominal pain
- 2nd: Change in bowel habit
- rectal bleeding in 25% - all patients with rectal bleeding should have an endoscopy

Staging: TNMClinical Prognostic Factors:

Age: incidence increases w/ age (mean 60)

Symptoms: obstruction/perforation

Blood Transfusion: can cause immunosuppression in the post-op period – decreases ability to combat tumor cells shed at the time of surgery

Adjacent Organ Involvement: T4 worse

Histologic/Biochemical/Genetic Factors

Histologic Grade: 3 grades, most grade 2 – preserved gland architecture

Mucin Production and MSI: hnpcc related, better prognosis

Signet-Ring: worse prognosis

Venous Invasion: poor prognosis

Perineural Invasion: poorer prognosis

Lymph Node Involvement: most important prognostic indicator – need at least 13 lymph nodes for adequate staging

CEA: glycoprotein absent in normal mucosa, present in 97% of CA; good for surveillance, not screening

- if elevated, preop, if resected and no mets, should decrease
- if > 15 mg/mL, high likelihood of mets

Sentinel Node: being studied

DNA Ploidy: nondiploid cells worse prognosis

Spreading Patterns:

Intramural: maximum 2 cm, 5 cm for colon suggested

Transmural: T stage, try for R0 resection

Margins: colon margins 5 cm, rectal distal 2 cm

Radial Margins: more important in rectal, but in T4's matters in colon as well

Transperitoneal/Implantation: ovaries, omentum, serosal or peritoneal surfaces at risk – carcinomatosis

- if localized, remove that structure

Lymphatic: risk by T stage

- T1: 9%, T2: 25%, T3: 45%

Hematogenous: less common than lymphatic; thought to be source for pulmonary mets

Detection of Synchronous Lesions: 6% or fewer patients

Screening Guidelines:

Low Risk: start at age 50

Moderate Risk:

- FamHx: 40yo or 10 yrs before FamHx Q5yrs
- Hx of > 1cm polyp: 1 yr after polyp'd then in 5yrs
- Hx of Colon CA: 1 yr, 3yr, 5yr, then at 10 yrs

High Risk:

- FamHx FAP: 12-14yo, then Q1-2yrs
- FamHx HNPCC: 21yo then q2yrs
- Hx Crohn's: 15 years after onset, Q1-2yrs
- Hx UC: 8 years after onset, Q1-2 yrs

28 Surgical Mgmt of Colon CancerPreOperative Preparation

Must know:

1. tumor location in bowel
2. stage of the CA
3. patient's physiologic status
 - ASA score, POSSUM and p-POSSUM scores

Mechanical Bowel Prep: all but one study have showed a higher anastomotic leak rate in prepped patients, with an odds ratio of 1.8

Right Colectomy – Technique

- no touch technique
- ligation at origin of ICA off SMA
- terminal ileum 5-15 cm from ICV to ensure vascular supply

Extended Right Colectomy:

- for any lesion involving the transverse colon including hepatic or splenic flexures
- must ligate the middle colic vessels

Left Colectomy

- take omentum with transverse colon
- option for anastomosis is retroileal right colon to rectum anastomosis to maintain orientation of the right colon

Sigmoid Colectomy

- high ligation of the IMA
- release the splenic flexure
- always do in lithotomy
- always do a leak test in the pelvis

Total Abdominal Colectomy and Ileorectal Anastomosis

- HNPCC, attenuated FAP, metachronous cancers
- end-to-end ok, can also do side to side

Special Circumstances

Prophylactic Oophorectomy: not recommended at this point

Concurrent AAA: >6 cm AAA either first or synchronous. EVAR mitigates this problem

Sentinel Node Assessment: not recommended right now.

Palliative Colectomy: should rarely be performed and only in patients with life-threatening comorbidities or advanced incurable disease

Outcomes of Colectomy for colon CA:

Stage I: 90%

Stage II: 65-90%

Stage III: 45-75%

Risk of locoregional recurrence after colectomy: 5%

Margins - Mural

- 5 cm proximal and distal for sure adequate
- more recent data suggests 2 cm from palpable tumor edge
- mural spread to ileum is very rare – so don't need to resect for margin, only vascularity

29 The Preoperative Staging of Rectal Carcinoma

Clinical Examination

Things to look for on Digital Exam:

- Location, morphology, number of quadrants involved, degree of fixation, mobility, extrarectal growths, direct continuity, separate

Clinical Staging System:

- CS1: Freely mobile – likely submucosa penetration
- CS2: Mobile w/ Rectal wall – muscularis propria pen'd
- CS3: Tethered Mobility – Perirectal Fat
- CS4: Fixed – adjacent tissues

CT Scan:

- unable to differentiate layers of rectal wall – can't do T stage
- unable to visualize lymph nodes < 1 cm
- unable to differentiate between inflamed vs. malignant nodes
- multidetector CT may improve the sensitivity of CT
- T-stage accuracy: 70%
- N-stage accuracy: 45%

MRI:

- accuracy depends on technique
- fascia propria well visualized when done phased-array coil or endorectal coil
- "MRI with a surgace coil provides useful information in patients with locally advanced rectal cancer."

Endorectal Ultrasound:

- learning curve, sensitivity improves with experience
- overstaging due to overreading of inflammation
- neoadjuvant therapy decreases EUS accuracy, so should be done prior to radiotherapy
- can't diff. between inflamed vs. malignant nodes
- T-stage accuracy: 95%
- N-stage accuracy: 80-85%

EUS vs. MRI:

- ERUS highest sensitivity & specificity for T stage
- MRI w/ endorectal coil: higher accuracy for N Stage

Distant Mets:

- CT of Liver limited to 1 cm or greater lesions
 - MRI liver more sensitive
 - PET w/ CT/MRI improved sensitivity
 - indications now post resection or for rectal CA w/u
-

30 Surgical Treatment of Rectal CancerColonoscopy:

- before all to detect synchronous lesions
- rate of synchronous polyps: 13-62%
- rate of synchronous CA: 2-8%

Total Mesorectal Excision:

- rectal mesentery removed sharply under direct visualization
- emphasize: nerve preservation, hemostasis, and avoidance of violation of the mesorectal envelope
- reduces positive radial margins from 25% to 7%
- decreases the rate of local recurrence
- however has higher leak rate (up to 17%)
- decreased rate of impotence
- adjuvant therapy improves outcome of TME
 - advised for stage II and III rectal CAs

Points during dissection that nerves can be injured:

- sympathetic plexus around aorta
 - results in retrograde ejaculation
- lateral pelvic sidewall: both para- and symp- chains:
 - results in impotence & bladder dysfunction
- anterolateral midrectum: hypogastric plexus & nervi erigentes

Distal and Radial Margins:

- radial margin sig. for local recurrence
- proximal margin of 5 cm
- distal margin of 2 cm

Techniques of Rectal Excision**Abdominoperineal Resection**

Position: lithotomy, elevate coccyx off of bed

Incision: surgeon preference

Mobilization: mobilize sigmoid and left colon.

- often begin at the pelvic brim
- splenic flexure rarely needs to be mobilized

Resection and Ligation: divide bowel at descending & sigmoid junction.

- SHA (and if IMA) should be ligated flush

TME: after vessel ligation, dissect down towards the promontory.

- Anterior dissection should include the two layers of Denonvillier's Fascia

Perineal Dissection: sew anus closed. Elliptical incision around the anus. Start anteriorly at the perineal body, laterally to ischioanal spines, posteriorly tip of the coccyx.

LAR w/ Sphincter Preservation

- need at least 2 cm margins

Coloanal Anastomosis

- for rectal cancer not invading the sphincters but LAR not technically possible
- level of transection is "stripped"
- start at dentate line and do a tubular mobilization of the rectum from intersphincteric groove
- *Colonic J-Pouch*: Fold rectum 5-8 cm on itself

- *Coloplasty*: 4-6 cm from distal end, longitudinal incision of 5-8 cm and then closed transversely
- higher rate of leaks

Local Excision

- should be < 4 cm and <40% bowel circumference
- transanal if < 5cm from anal verge, or then TEM

Transanal: prone position, pudendal nerve block assists with visualization

- traction sutures 1-2 cm distal to tumor
- line of dissection marked 1-2 cm border
- full thickness dissection – should see peri-rectal fat
- closure with 3-0 interrupted vicryls

TransCoccygeal Excision (Kraske)

- mid-distal rectal lesions, usually posterior
- prone-jackknife position
- midline incision over sacrum to posterior border of EAS
- coccyx and sacral coccygeal joint removed
- levator ani next, incised midline
- palpation and 1 cm margins
- allows for removal of lymph nodes
- air test, and then close all layers (except bone)
- 5-20% rate of fecal fistula, most heal w/ diversion

Transphincteric Excision (York-Mason)

- start like Kraske, but divide EAS and levators in midline posteriorly
- remain in midline to avoid nerve supply laterally
- higher risk of incontinence, so Kraske preferred

TransAnal Endoscopic Microsurgery (TEM)

- scope 4 cm in diameter, 12-20 cm length
- allows for more proximal lesions
- low adoption rate due to expense and training

Major Risk Factors for Local Recurrence

- depth of invasion
- positive surgical margins
- histologic grade
- Node positivity

Rate of Nodal involvement by Depth - & Rx Recs:

- T1: 12% - Surgery Alone –
 - pos. margin/node pos → chemorads or radical Rsn
- T2: 22% - Op + chemoradiation
 - pos. margin/node pos → radical Rsn
- T3: 58%
- T4: 58%

Survival After Rectal Cancer Excision

- Stage I: 85-100%
- Stage II: 60-80%
- Stage III: 30-50%
- *Synchronous*: 3.5%

T4 Lesions – Exenterations

- 5 year survival >50% with extended resections, if margins are tumor free
- inflammatory ingrowth fair better than infiltration

31 Adjuvant Therapy for Colorectal CA**Colon Cancer**

Stage at Presentation: most sig. prognostic factor

Stage I: 95% 5 year w/ surgery alone

Stage III & IV: adjuvant

Stage II: unclear if adjuvant necessary

Adjuvant Therapy for Stage III Disease:

Stage III 5 year: 30-60%

- Adjuvant therapy improves survival 10-15%

Standard Systemic Chemo in US: 5-FU & Leucovorin

Important Trials:

- *NSABP CO-1*: 8% improved 5 year survival Stage II and Stage III disease with MOF (semustine, vincristine, 5-FU)

- *NCCTG*: 5-FU + Levamisole significantly decreased recurrence rates in stage III (Duke's C)

- *Intergroup 0035 Study*: confirmed efficacy of 5-FU + Levamisole

- *NIH*: consensus statement for 5-FU + Levamisole

Leucovorin (LV) emerged as better agent than Levamisole

- *IMPACT Trial*: 3-year NED from 62% - 71%

- *NCCTG/NCIC*: 6 month therapy superior

- *NSABP CO-4 Study*

- *QUASAR Collaborative Group*

New Standard: 6 months 5-FU/LV for Stage III disease

Oxaliplatin as additional modulator (FOLFOX)

- *MOSAIC trial*: 23% decrease in recurrence 3-year

- *PETACC*

Adjuvant Therapy for Stage II Disease (node negative)

Still controversial

- *SEER-Medicare Cohort*: no advantage (72 vs 74%)

- Meta-analysis of NSABP trials CO-1,2,3&4: adjuvant therapy beneficial for stage II

- noted to have major methodological flaws

For a good answer: need 5000-800 patients

Radiotherapy

Most important risk factors for recurrence:

1. pathologic staging
2. tumor fixed in retroperitoneal part of colon
3. perforation or obstruction by cancer

Role in colon cancer still undefined.

- wide variations in radiation techniques, doses and concurrent use of chemo, make difficult to define

Treatment should be individualized to patients at high risk of local recurrence

Immunotherapy, Tumor Vaccines and Gene Therapy

Still under study. No definitive therapy as of yet.

RECTAL CANCER

Clinical benefits of Radiotherapy in rectal CA:

1. lowers local failure rates & improve survival
2. allows surgery in nonresectable rectal CA
3. facilitates sphincter-preserving procedures
4. may offer totally curative approach w/o surgery

Benefit 1: lowers local failure rates & improves survival

- *Uppsala trial*

- *NSABP R-03 Trial*: 44% vs 34% NED at 1-year

- *German CAO/ARO/AIO Trial*: 6 vs 13% at 5 years

Neoadjuvant Therapy: Radiation alone vs. Chemorads

- preop: decreased small bowel toxicity, decreased overall radiation associated complications, decreased risk of tumor seeding during surgery; Risk: overtreating

- ERUS & Pelvic MRI decrease risk of overtreating

- *Dutch Trial*: 1861 patients TME w/wo radiation

- 2 year recurrence: 8.2% to 2.4%

- 5-year recurrence: 11.4% vs. 5.6%

- 5-year survival equivalent between the two

- *EORTC 229121 Trial*: evaluating chemoradiation preop

Postoperative Radiation vs. Chemoradiation:

NIH 1990 consensus statement: combined modality for Stage II and III disease

Benefit 2: Radiotherapy allows Surgery in nonresectable Rectal CA

Tumor that cannot be resected without a very high risk of local recurrence

Short course radiotherapy does not work (20-25 Gy 1 wk)

- standard dose: 45-55 Gy over 5-6 weeks

- 6-8 week waiting period allows it to shrink

No good evidence to support this treatment, but most follow this paradigm

Benefit 3: Radiotherapy facilitates sphincter-preserving procedures in low-lying rectal CA

5-10 mm distal margin now being accepted as curative

- *French R9001 Trial*: local recurrence rate 12% among the patients in whom the surgeon had originally planned APR but changed intraop due to "downsize"

- At this time, there is no evidence that prolonged-course radiotherapy combined with chemotherapy with delayed surgery impacts sphincter preservation

- up to 20% of LAR patients incontinent to solid stool. On surveys, lower quality of life than those with stoma

Adjuvant Chemo alone in Rectal CA

Combo 5-FU/LV found to improve survival in pt's w/ colon CA, but not w/ Rectal CA.

32 Colorectal CA Surveillance

TYPES OF SURVEILLANCE

Metachronous Colorectal Neoplasms

Risk of Metachronous polyps: 30-56%

Risk of Metachronous CA: 2-8%

Original screening advocated at 1 yr, but now ASCRS recommending to start at 3 years if all preop screening appropriately completed. If not, then at 6 months.
- if negative at three years, can continue Q3-5 years

Recurrent Cancer

Only 2% of local recurrences can be visualized on colonoscopy

- more likely with rectal CA than colon

If had transanal excision, Q3 months ERUS to eval
CEA: Q3 months first 2 years, then Q6 months next 3 years
CXR: Q6-12 months
No evidence for routine screening with CT, MRI or PET

Hereditary Cancer:

Thought to play a role in 10-25% of colorectal CAs
- consider if <50 years of age, or 1st degree relative with it

Risk & Pattern of Recurrence

60-80% of recurrences w/in 2 years of surgery
90% by 5 years
So follow up most intense during first 2 years, taper over next 3
10% of recurrences will be able to have R0 resection

33 Mgmt - Local Advanced/Recurrent Rectal CA

Locally advanced Dz: in 5-12%

- goal of surgery: wide en bloc Rsnx & involved organs

Local regional recurrence: in 7-33%

- 20% will be cured by curative resection
- Most important factor: stage of disease at presentation
 - other factors: perforation, obstruction, T4, mucin production, LVI
- 90% of recurrences occur in the central or posterior pelvis
- 19% occur at the anastomosis

T4 Tumors:

- fixed on physical exam/invasion adjacent organs
- R2 resections – mean survival time less than a year

PREOPERATIVE EVALUATION & PATIENT SELECTION

If patient overall condition restrictive, may choose palliative surgery with chemoradiation (even if can do full resection)

- ASA IV or V not candidates for surgery

If patient is acceptable for surgery:

- all need scope to rule out synchronous lesion
- CT A/P w/ con: r/o extrapelvic spread, extent of disease and adjacent organ involvement
- Hepatic lesions: need ultrasound, and if suspicious bx
- CXR or Chest CT: lesions biopsied
- PET: higher sensitivity for recurrence than CT for colorectal CAs (90 v. 71%)

3 ways to differentiate postop changes from tumor:

1. change in the lesion (e.g. interval size increase)
2. invasion of adjacent organs
3. histologic evidence via endoscopy/CT/US

CEA rising but no evidence of disease:

- histologic proof should be sought
- exploratory pelvic surgery not recommended to eval

DETERMINING RESECTABILITY

Classification of Tumor Resectability:

- F0: not fixed to any pelvic organ or structure
- FR: fixed by resectable
 - divided into anterior, posterior and lateral
- FNR: fixed and NOT resectable

Symptoms or findings suggestive on unresectable for cure:

Sciatic pain, Bilateral Ureteral Obstruction, Multiple points of tumor fixation in the pelvic sidewall, Circumferential involvement of pelvic sidewall, S1/S2 bony or neural involvement, Extrapelvic disease

MULTIMODALITY RX - ADV/LOCALLY RECURRENT RECTAL CA

Radiotherapy: for local control

- alone does not offer significant chance of cure

Chemotherapy: for system disease

- Initial: Full course of EBRT (5040 cGy) w/ 5-FU chemo
- Recurrent: 2000 cGy EBRT w/ 5-FU before surgery

- most synergy with IORT at 8 weeks

- reimaging at 4 weeks, if no progression can do surgery

SURGERY

FR lesions:

- Posterior: needs posterior sacrectomy (Not for S1&S2)
 - One S3 root usually sufficient to preserve bladder function
 - will need bilateral ligation of internal Iliac A&V (for S3&4)
- Anterior:
 - may need posterior vaginectomy up to en bloc hysterectomy
 - men: may need cystectomy or cystoprostatectomy

USE OF IORT

For R1/2 resections, or close margins

1000 – 2000 cGy delivered

- 1000: minimal residual disease
- 1500: gross residual disease <2cm
- 2000: unresectable or gross disease >2 cm

RESULTS OF MULTIMODALITY TREATMENT

Reports up to:

94% for stage II, 85% for stage III

Recurrent disease with curative intent surgery vs. palliative:

- 5-year survival: 35% vs. 7%

Local control rates w/ multimodality: 25 – 78%

Long-term survival: 25 – 40%

304 patients followed at Mayo prospectively for recurrent CA

- 138 (45%) had R0 resections
- 1-, 3-, & 5- yr survival rates: 84%, 43%, 25%
 - 5-year R0 vs. R1/2 Rsnx: 37 vs. 16%
- R2 resection decreased survival with surgery
- best survivors: asymptomatic or nonfixed tumors (41%)

PALLIATIVE CARE FOR ADVANCED OR RECURRENT RECTAL CA
Radiation:

- full dose Rx (if no prior) effective for bleeding, pelvic pain, near obstruction
- effective for pain 50-90%, however most will recur w/ progression
- 2-year survival: 25%

Minimally Invasive means:

- ureteral stents: for urinary obstruction
- expandable metal colonic stents (effective in 90%)
- Endoscopic Lasers: remove the tissue intraluminally by coagulative necrosis, tissue vaporization; becomes less effective with disease progression

34 Colorectal CA: Metastatic (Palliation)

Vast majority of Stage IV not curable.

- 5 year survival rate in 2000: 8%
- median Survival 21 months (now)

DIAGNOSIS & STAGING

Initial:

- colonoscopy, bx
- ERUS or MRI if Rectal
- CT C/A/P
- PET detects 20% of CT false negatives (indicated if will change mgmt)

Three Important decisions:

1. Patient fit for aggressive treatment?
2. Does tumor present sig. risk of bowel obstruction?
3. Can Mets be resected?

PALLIATIVE MGMT

Majority of obstructing CAs Stage III or IV

- Risk of cecal perforation w/ competent IC valve

Non-Resective Palliative Options:

- (1) *laser therapy*: for rectal CA (or distal sigmoid) – 85% success, however needs multiple therapy sessions, risks of bleeding, perforation and severe pain.
- (2) *fulguration*: removes bulk of tumor but requires admission and anesthesia
- (3) *colonic stents*: can potentially dilate lumen to near-normal diameter; minimal sedation necessary, can be placed in long lesions by overlapping stents
- (4) *diversion*

SURGICAL MGMT – RESECTION

No randomized data demonstrating a survival benefit for bowel Rsn in stage IV dz

Standard Mgmt: systemic chemotherapy

LIVER METASTASIS

60% of colon CA will have liver Mets

- 1/3 of those will be isolated liver mets
- 10% candidates for resection
- 30% of those candidates will get long-term survival

LUNG METS

Rule of 10s

- 10% will have lung mets, of those –
- 10% will have isolated lung mets, of those –
- 10% will be considered resectable

5 year survival after Rsn: 30-40%

- poor data on actual outcomes

PERITONEAL METS

In 10-15% of patients

Second most common met site after liver

Two classification systems:

(1) Gilly's: by dimension of the implants

(2) Peritoneal Cancer Index of Sugarbaker: tumor size in 13 regions of the abdomen

Historical survival data with peritoneal mets: 6-8 months

OVARIAN METS

Metastatic Colon vs. Ovarian Primary:

Ovarian: CK20⁺/CEA⁺/CK7⁻

Colon: CK20⁺/CEA⁻/CK7⁺

No good studies to establish resection benefit

Needs to be discussed with patients and families

BONE AND BRAIN

Surgery only for isolated single brain mets – can result in survival beyond 1-2 years

Bone Mets: consider radiation and medical therapy for symptomatic relief.

35 Anal CancerANATOMIC CONSIDERATIONS

Intraanal: lesions that cannot be visualized at all or incompletely w/ gentle traction on buttocks

Perianal: completely visible, w/in 5-cm radius of anal opening

Skin: outside of 5-cm radius of anal opening

Transition Zone: 0-12 mm in length from dentate line to proximal. Transitional urothelium. May have squamous metaplasia overlying normal rectal mucosa. Can extend up to 10 cm proximal.

TERMINOLOGY

Pathologists use varying terms for same meaning – CIS, AIN, Anal dysplasia, SIL & Bowen's all may mean the same thing

Recommendation – just use one of four terms:

1. normal
2. low-grade squamous intraepithelial lesions (LSIL)
3. high-grade squamous intraepithelial lesions (HSIL)
4. Invasive Cancer

LYMPHATIC DRAINAGE

- Above Dentate: S. Rectals to Inf Mes LNs & Int. Iliac LN
- Below Dentate: inguinal nodes, may also be above nodes

ETIOLOGY AND PATHOGENESIS OF ANAL CA

- HPV necessary but insufficient
 - DNA papovavirus
 - CA Serotypes: 16, 18, 31, 33, 35
 - MC serotypes: 6, 11 – low malignant potential
 - transmission not prevented by condoms – virus pools at base of penis and scrotum (only abstinence works)
 - women: pools vagina to anus
 - anal condyloma does not require anal intercourse
 - requires *disruption in mucosal barrier of skin* to enter or transitional epithelium very susceptible
 - *Cell mediate immunity* important block to virus
 - Viral Genes to remember: E7, E6, E2, affect p53 & Rb
- HIV+ patients:
 - more likely to have HSIL
 - More likely to go from LSIL to HSIL w/in 2 years
 - increased risk w/ CD4 count <200
- Acetic acid and Lugol's solution with colposcope or Loupe's will help visualize the lesions

BOWEN'S DISEASE

- Bowen's Disease: both SCCA in situ and HSIL – depends on pathologist's training, no reliable term - t/c HSIL
- often times incidental finding in a hemorrhoidectomy
 - in immunocompetent, <10% will progress
 - higher rate of progression if immunocompromised
 - unknown predictors of progression – so recommendation for now is treat Bowen's (unless advanced age and asymptomatic or severe other health risks)

Treatment:

- (1) Incidental finding: 1-cm random biopsies starting at dentate line, send for frozen. Positive areas undergo wide excision w/ 1 cm margins
 - risks of incontinence, stricture/stenosis, recurrence
- (2) Acetic Acid/Lugol's: diathermy on the visualized lesions
 - in immunocompetent – zero progression and recurrence
 - HIV+ - higher recurrence but little progression
 - can resect with minimal margins this technique as well
- (3) Other options, less data – 5-FU cream, Imiquimod, PDT, XRT, Laser, combos – try in complicated case

Follow-Up:

- HIV+: yearly pap-smear
- HIV-: pap-smear every 3 years

SCC of Anal Margin

Skin from dentate to 5 cm radius externally

- different expressions of cadherin, cytokeratins, & p53 than normal anal CA – different cancer

Clinical Characteristics

Similar to skin SCC, staged likewise

- 70s, M=F

Staging

- based on size and nodal status of tumor
- Lymphatics: femoral & Ing. LNs, ext & com iliac LNs
- Venous: inferior rectal vein

Treatment Options

- Tis, T1 lesion: local excision w/ 1 cm margin
- T2 lesion: XRT 1st, in select local excision w/ 1 cm margin
- T3/T4: XRT including pelvic and groin nodes
 - 5-FU and mitomycin
 - Persistent/recurrence – may need re-excision/APR

Local Recurrence rates:

T1: 50-100%, T2: 60-100%, T3: 37-100%

SCC OF THE ANAL CANAL

- Includes: epidermoid, cloacogenic, mucoepidermoid CAs

Clinical Characteristics:

- bleeding MC symptom
- others: tenesmus, d/c, incontinence, inguinal LAD
- most diagnosed late

Evaluation:

- DRE, procto, ERUS
- if nodes enlarged, consider FNA
- CT A/P, CXR

Staging:

- based on tumor size and nodes
- T stage T1 <2 T2 <5 T3, T4 invades deep structures
- N stage: N1 perirectal v. N2 unilateral v. N3 bilateral

Treatment:

ChemoRadiation: Nigro Protocol – 1st line

- 5-FU and mitomycin C
- external or brachy ok – 30 – 60 Gy
- decreased cure rate (50%) if over 5 cm

- late complications: anal necrosis, stenosis, ulcers, diarrhea, urgency, FI, SBO, urethral stricture
- Cisplatin: gaining favor over mitomycin C
 - radiation sensitizer
 - less myelosuppressive

Follow up:

DRE and Procto: Q2mo 1st yr; Q3mo 2nd year; Q6 mo →

Treatment of Residual Disease:

- re-stage the patient
- salvage therapy can be given
- Surgery: APR
 - use plastics for flaps to improve wound healing
- Poor prognosis:
 - nodal disease
 - positive margins
 - persistent disease after neoadjuvant
- Isolated liver and lung mets: t/c resection

UNCOMMON ANAL CANAL NEOPLASMSADENOCARCINOMA

3 types – based on source:

- (1) mucosa of transitional zone – same as rectal CA
- (2) Base of anal glands
- (3) from a chronic anorectal fistula

More aggressive than SCCs; 60's, M=F

- Rectal type is only one that *may* be amenable to local resection – all others must have an APR
- Chemoradiation – little data, but prelim data supports it

MELANOMA

< 500 reported cases; Usually Caucasian Women in 60s

- late presentation for most
- Anorectal bleeding MC symptom
- Arise from: transitional zone, anoderm or mucocutan jxn
- most pigmented, some polypoid – may look like a thrombosed hemorrhoid
- Surgery only chance for cure
 - if > 10 mm thickness – no treatment will cure
 - 35% present with nodes
 - local excision vs. APR – does not seem to affect survival – all have dismal prognosis
 - for now advocate APR for all lesions > 4mm thick
 - if < 4mm thickness – discretion
 - if signs of metastatic disease – APR not advised
 - do APR if: lesion > 1-2 cm, sphincters involved
- Adjuvant Chemoradiation being evaluated – no standard

GASTROINTESTINAL STROMAL TUMORS (GIST)

- only 17 reported cases; Men 50s -70s
- *mesenchymal* origin; *CD34* & *CD117* antigens
- most asymptomatic; symptomatic worse prognosis
- Prognosis: worse with
 - size > 5cm,
 - high mitotic counts,
 - pleomorphisms,
 - infiltration of fascia propria,

- coagulative necrosis

- Treatment:

- local excision: if < 2 cm
- APR: if > 2cm, or one of findings above

SMALL CELL CARCINOMA/NEUROENDOCRINE TUMORS:

< 1% of all colorectal CAs

- hyperchromatic nuclei, pale nucleoli, high mitotic count
- not disseminated → radical resection w/ ChemoXRT
- disseminated (~75%) → chemo-XRT (cisplatin & etoposide)

UNCOMMON ANAL MARGIN/PERIANAL NEOPLASMSBASAL CELL CA

- 70 yo Men
- sun not etiology, synchronous lesions common
- most < 2 cm at presentation
- little invasive and metastatic potential
- must differentiate from Basaloid CA which is different
- Treatment: WLE, may require Moh's or flaps/grfts
 - survival ~100%

PAGET'S DISEASE

- Paget's Cells: intraepithelial adenoCA w/ a prolonged preinvasive phase that eventually develops into an adenoCA of underlying adocrine gland
- 70's; M=F
- Sx: *itching* MC, bleeding, mass, LAD – median 3 yrs
- Mimics many other disease – *Biopsy* essential for diag
- Histology: large round eccentric hyperchromic nuclei
 - vacuolated cytoplasm
 - Positive on Acid Schiff stain ← mucin
 - positive stain: mucoproteins
- Treatment: based on invasion
 - *NonInvasive*: WLE to grossly negative margins
 - must also do mapping with random circumferential biopsies sent for frozen section – to include 1 cm border, dentate line and anal verge. *Toluidine Blue* & *Acetic Acid* staining help identify biopsy sites
 - *Invasive*: Radical Resection
 - *Positive Nodes*: also do lymph node dissection
 - *Adjuvant Therapy*: efficacy unknown at this time

VERRUCOUS CARCINOMA

- AKA giant condyloma or Buschke-Lowenstein Tumors
- measure from 1.5 – to 30 cm
- invade locally – cause fistulas, necrosis, tissue loss
- Treatment: radical local excision
 - APR if: deep tissue invasion, multiple fistula, sphincters
 - Neoadjuvant: may help downstage

HIV-RELATED ANAL CANCERKAPOSI'S SARCOMA

- rare, look like hemorrhoids
- treatment: chemotherapy

LYMPHOMA

- NHL, in anal mucosa is a MALT
- Sx: pain, pruritis, drainage, mass
- Treatment: Chemo-XRT, No role for surgery

36 Presacral TumorsAnatomy and NeurophysiologyNerves:

- If upper three sacral nerve roots left intact on either side – anorectal function preserved
- if both S-3 roots taken: EAS will not contract → FI

Sacrum:

- majority can be resected – if >50% of S1 remains, pelvic stability will be maintained
- but if preop radiation, S1 alone will get stress fx

Classifications: Congenital, Neurogenic, Osseous, Misc, Liposarcomas – all into benign vs/ malignant

GROSS AND HISTOLOGIC APPEARANCE

Epidermoid Cyst: results from closure defect of the ectodermal tube. Stratified squamous cells, no skin appendages, typically benign.

Dermoid Cysts: arise from ectoderm, have skin appendages. Benign. May communicate with skin as a skin dimple.

Enterogenous Cyst: originate from sequestration from developing hindgut. Endodermal – so can be lined w/ squamous, cuboidal or columnar. Multilobular w/ one dominant lesion and small satellite ones. Most benign.

Tailgut Cysts: cystic hamartomas, multilocular cysts.

Glandular vs. transitional epithelium. Most Benign.

Teratomas: include all three germ layers; Benign but can become SCCs or Rhabdomyosarcomas. Associated *vertebral, GU or anorectal* abnormalities. MC female pediatrics. Malignant transformation MC in adults.

Sacrococcygeal Chordoma: MC malignancy in presacral space – originate from *primitive notochord*; Men >30yo may invade, distend or destroy surrounding tissue

Anterior Sacral meningoceles: result from defect in thecal sac & may be with a presacral cyst or lipoma; *headache* worse with straining or coughing. Other associated anomalies (Spina bifida, vaginal duplication) – Rx: *ligation of Dural Defect*

Neurogenic Tumors: different ones, MC neurilemoma; grow slowly; need to determine if benign or malignant

Osseous Tumors: arise from bone, cartilage, marrow, fibrous tissues; rapid growth; *lungs* MC site of mets; all associated with *sacral destruction*;

HISTORY AND PE

- DRE: extrarectal mass displacing rectum anteriorly
- ill-defined symptoms, may see psych
- recurrent fistulas
- perianal dimple

DIAGNOSTIC WORKUP

- CT and MRI mainstay – eval neurovascular and bony involvement of tumor for planning

PREOPERATIVE BIOPSY:

- Recommended for – solid & heterogeneously cystic
- never do transvaginal or tranrectal – will infect lesion
- transperineally or transsacrally

- biopsy tract has to be removed with specimen

NEOADJUVANT THERAPY:

- preop allows smaller area of radiation
- decreased tumor size
- decreased wound allows for sooner systemic therapy

Multi-disciplinary Team

CRS, Neuro, Spine, Urology, Vascular, Plastic, Rad Onc, Med Onc – include all necessary specialists

SURGICAL APPROACH:

Below S3 – transperineal alone may be enough, if above S3, will likely need combined approach

Preop:

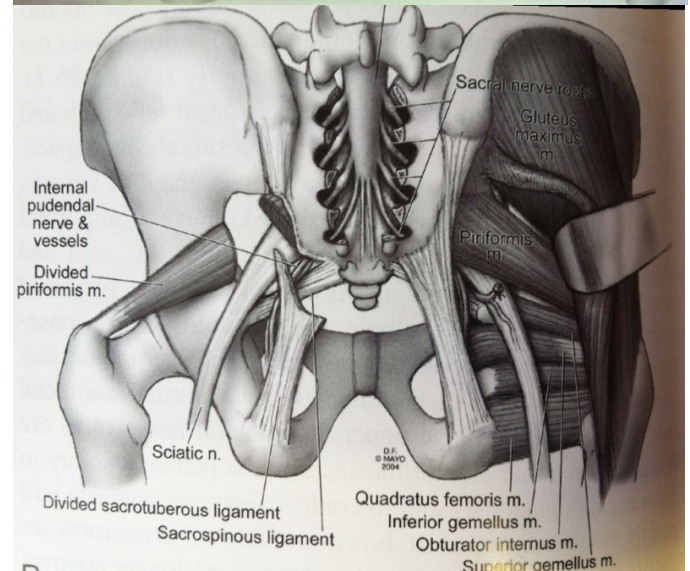
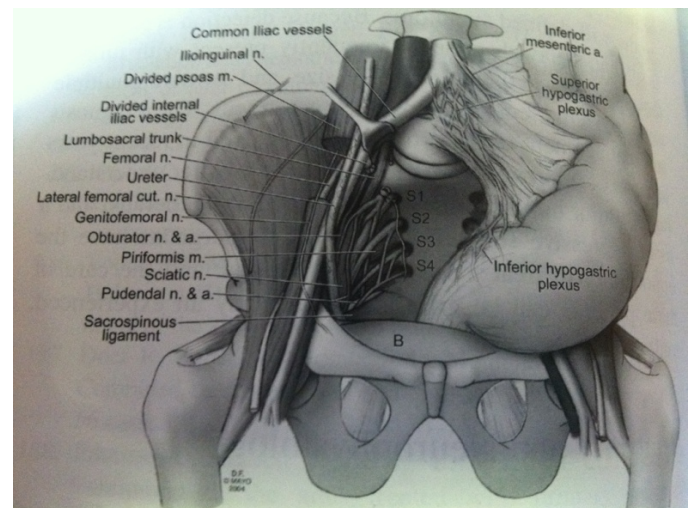
- consider temp IVC Filter if long op – high risk of DVT
- massive transfusion may be necessary

Posterior Approach (Kraske):

- Prone Position
- incision over lower portion of sacrum (avoid EAS)
- lower sacrum or coccyx can be excised en-masse

Combined Abdominal & Posterior Approach

- if extends above S3
- can ligate internal iliac A - try to preserve Ant. Division
- may need TRAM Flap



37 Miscellaneous TumorsCARCINOIDS

- from enterochromaffin cells – endocrine system

Pathology:

- small round cells with uniform nuclei & cytoplasm
- electron-dense neurosecretory granules w/ small clear vesicles – same as synaptic vesicles in neurons
- able to take up & reduce silver stains due to serotonin
- *Chromogranin*: immunohistochemical stain to identify

Carcinoid Tumor Growth Patter

	Pattern	Pearls	Freq	Prognosis
A/I	Insular	Solid nests; peripheral palisading	1	Favorable
B/II	Trabecular	Ribbon-like	2	Favorable
C/III	Glandular	Tubular, acinar, rosette	4	Poor
D/IV	UnDiff'd	No recognizable pattern	3	Poor
Mix	Mixed	Any combo of above		Favorable

Pathophysiology

- produce >30 bioactive compounds – amines, proteins, prostaglandins – serotonin MC
- Serotonin: 2 stage metabolism – Tryptophan → 5-HTP – decarboxylation → 5-HT (serotonin)

Systemic Symptoms – “Carcinoid Syndrome”

- 3 main symptoms
 1. Vasomotor Sx – flushing & BP changes
 2. Diarrhea
 3. Bronchospasm
- Liver metabolizes & inactivates compounds – so syndrome only occurs if there are liver mets or primary is outside of portal venous system
- 4 types of flushing:
 - Type 1: diffuse eryth. Rash < 5 min - early stage mets
 - Type 2: violaceous rash, telengectasias < 5min – late
 - Type 3: bronchial tumors
 - Type 4: Gastric Tumors
- Cardiac: serotonin acts on myofibroblasts → fibroplasia → increased vasc tone → bronchoconstriction & Plt Aggregation
 - Left side of heart protected by lung which inactivates
- Carcinoid Crisis: by anesthesia, manipulation, stress – profound flushing & hypoT, arrhythmias, bronchoconstriction.
 - can avoid by pretreatment with somatostatin and histamine blockade

Diagnostic Studies:

24-UA for 5-HIAA –

- avoid foods rich in serotonin – banana, pineapple, Kiwi, plums, walnuts, avocados, pecans, tomatoes
- avoid meds: Guaifenesin, Acetaminophen, Salicylates, L-Dopa

Prognosis

- staging same as adenoCA
- Stage I: 82%; II: 95%; III: 83%; IV: 38%

Treatment

- Surgical resection
 - Appendix: appy if <1 cm, R Hemi if >2, in b/t choice
 - SB: Local – resection of primary, extensive – debulk
 - Col/Rect: < 1cm local, >2 segment – in b/t choice
 - Liver Mets: Rsnx improves survival from 20 → 70%
- Systemic Therapy:
 - Palliative: by symptoms or octreotide 400 µg/day
 - Chemo: poor overall results;

GI STROMAL TUMORS

- stain + for CD 117, KIT protooncogene marker
- CD 34 positive in 60-70%
 - Leiomyoma neg staining for these (positive for desmin and smooth muscle actin)
- interstitial cells of Cajal
- Stomach MC, then SB
- rarely spread to lymphatics, so radical resection may not be necessary – try local, wide margins not necessary
- Imatinib (Gleevec) – selective tyrosine kinase inhibitor

LEIOMYOMAS

- small, arise from smooth muscle of muscularis mucosa
- stain negative for CD117, positive for desmin, actin
- almost always incidental finding
- great prognosis, low recurrence rate

SQUAMOUS AND ADENOSQUAMOUS CARCINOMA

- Mean age: 58-66
- present at advanced stage
- Stage I&II – same prognosis as adenoCA
- Stage III & IV: worse prognosis
 - stage III: 24%

LYMPHOMAS

- MC stomach/small bowel (10% in colon)
 - 70% of colon R sided
- MC: non-Hodgkin's Lymphomas, B-cell origin, diffuse large cell type

Dawson's Criteria for GI Lymphoma:

1. absence of enlarged superficial LNs
2. no enlargement of mediastinal LN
3. Total & differential WBC are the same
4. at ex lap, only regional nodes have disease
5. liver and spleen unaffected

Treatment: Surgical excision

EXTRAMEDULLARY PLASMACYTOMA:

- multiple myeloma MC, very rare only 22 reported
- urine Bence-Jone proteins, BM biopsy
- Path: localized collection of monoclonal plasma cells
- Rx: Rads & surgery

MELANOMA; in colon extremely rare – 4 case reports over 40 years – metastatic to GI tract MC

- if isolated, surgery is indicated, improves survival

COLONIC COMPLICATIONS OF LEUKEMIA

- neutropenic enterocolitis – detection of bowel wall thickening on ultrasound portends poor prognosis
- Rx: bowel rest, TPN, broad spectrum Abx
- surgery only for perforation or intractable bleeding

38 Hereditary Nonpolyposis Colon Cancer

5-6% of colorectal CA have germline mutation

HNPCC accounts for 3% of colorectal CA annually

HNPCC Traits:

- mean age 45 (earlier diagnosis)
- multiple generations affected
- proximal to splenic flexure
- poorly differentiated
- increased frequency synchronous/metachronous Dz
- Endometrial, ovarian, gastric, small Bowel, HB, transitional cell CA
- autosomal dominant inheritance
- mismatch repair (MMR) gene mutation

History

- unique genetic abnormality – replication error phenotype (RER+)
- Microsatellites instability areas of errors
- E.Coli research found MMR genes

Genetics – Microsatellite

- short tandem repeating base sequences
- usually mononucleotide or dinucleotide base repeats
- repeats found in noncoding or *intronic* portion of gene
- MC: repeats of adenine/thymine or CA or GT
- if sequence in cancer cell different than surrounding tissue – termed *microsatellite instability*

Genetics – Different type of DNA Repair

- *Base Excision Repair*: repairs based damaged by oxygen radicals.
- *Nucleotide Excision Repair*: repairs damage caused by exogenous agents (rads, chemo, UV)
- *MMR*: repair single base mismatches as well as insertion/deletion loops of up to 10 nucleotides
 - dysfunction is characterized by MSI → HNPCC
- *Loss of Heterozygosity*: Loss of whole portions of chromosome alleles → sporadic Colon CA

Genetics – MMR Function in Single Cells

3 main parts of the repair system: MutS, MutL, MutH

- *MutS*: finds mismatched DNA and forms it into a loop
- *MutL*: locates the the looped DNA
- *MutH*: excises the looped DNA
- DNA polymerase resynthesize new DNA strand

Genetics – MMR function in Humans:

- *MutS*: 5 identified MSH2 – 6
 - MSH3 & MSH6 have to both be abnormal to have loss of MMR
- *MutL*: 4 identified MLH1, PMS1, PMS2, MLH3
- *MutH*: equivalent for humans not identified yet
 - maybe S&L act without H?

Genetics – Gene Implicated in HNPCC Carcinogenesis:

- *TGFβRII* – Strong inhibitor of epithelial growth. A tumor suppressor gene. 10 adenine-repeating tract in its coding area. Found mutated in 70-90% of cancers w/ MSI.

- *IGFRII*: tumor suppressor gene – long 8 repeat of guanine tract.

- 90% of tumors have one of the above, but not both
- *BAX Gene*: in 54% of MSI colon tumors. Involved in apoptosis, activated by p53. Highly susceptible to frameshift mutations.

Pathologic Features of HNPCC Tumors

- mucinous or poorly differentiated signet ring cells
- lymph node incidence is 35% (sporadic 65%)
- diploid tumors, large chromosomes not lost

Clinical Features of HNPCC Tumors

- Colon CA in 80% (median age 42),
- endometrial in 50-60% (median age 49)
 - 75% chance of developing other CA
- Proximal to splenic flexure in 68% (49% sporadic)
- Synchronous Lesion 7% (1% sporadic)
- Metachronous CA at 10 yrs 29% (5% sporadic)
- 1 of 2.8 polyps removed has CA (1:41-119 in sporadic)
- malignancy transformation 3 yrs (10 yrs sporadic)

Genotype-Phenotype Relationships

Muire-Torre Syndrome: sebaceous adenomas, sebaceous carcinomas, & keratoacanthomas associated w/ multiple visceral tumors. 25% develop polyps, 90% of which will become CA.

Diagnosis

Original Amsterdam Criteria modified because it didn't:

- account for extracolonic malignancies
- decrease in average family sizes
- late onset variants of HNPCC
- problems with incomplete data recovery

HNPCC is a *clinical* diagnosis and genetic testing cannot prove a family does not have HNPCC.

Genetic Testing

- gene sequencing of MSH2 and MLH1
- *InSiGHT*: databank of all known mutations of these genes

Surveillance

- Colonoscopy Q2yrs starting at age 21, then Q1yr at 40yrs of age
- Annual Transvaginal ultrasound of endometrium with endometrial aspiration starting b/n 25-35 yrs

Treatment

- Colectomy with Ileorectal Anastomosis
 - then annual flex sig of rectum
 - 12% rectal CA at 12 yrs
- if patient very young or poor compliance with follow up then do TPC w/ IPAA
- if finished childbearing, strongly consider concurrent TAHBSO

Prognosis

- survival rate better than sporadic
- chemotherapy in MSI patients equivocal if helps

Modified Amsterdam Guidelines

- Two 1st degree relatives w/ colorectal CA involving 2 generations
- At least one before age 55 or a 3rd relative w/ endometrial or other extracolonic HNPCC tumor

39 IBD: Diagnosis & EvaluationEpidemiology

- Average Age of Onset:
 - Crohn's: 30s
 - UC: 40s
- hygiene hypothesis – too protected in childhood

SIGNS AND SYMPTOMSCrohn's Disease:

- affects mouth to anus
- discontinuous
- full thickness
- abdominal pain & diarrhea 75%, bleeding 40-60%
- anal disease in 10-20%
- most common in ileocecal region (40%)
- Waxing and waning course

Vienna Classification: 3 categories – progress b/n them
(B1) Inflammatory, (B2) Strictureing, (B3) Fistulizing

Ulcerative Colitis:

- starts at rectum goes proximal
- continuous
- symptoms depend on extent & location of disease
- Mucosal disease

EXTRAIESTINAL MANIFESTATIONSMusculoskeletal:

- MC complaint
- osteopenia & -porosis very common
- Ankylosing Spondylitis
 - HLA B27 in 5% of CD and UC
- anti-TNF shown to be beneficial

Cutaneous:

- More common in CD
- Pyoderma Gangrenosum:
- Erythema Nodosum:
- aphthous stomatitis & pyostomatitis

Hepatobiliary:

- Primary Sclerosing Cholangitis (PSC) 3% in CD=UC
- PSC in UC raises risk for colon CA

Ophthalmologic:

- Iritis, uveitis, blurred vision, eye pain, photophobia
 - require prompt treatment
- episcleritis: sclera injxn, burning, tearing;
- in 2-8% of CD & UC; unrelated to disease activity

Coagulopathy:

- increased risk of DVT, Mesentric Thrombosis, PE
- decreased protein S and antithrombin III levels

DISEASE SEVERITY ASSESSMENTCrohn's Disease:

- CD activity index (CAI) – measures 8 factors
 - total score <150: quiescent disease
 - Total score >450: severe active disease
- requires a 7 day diary; more for research
- Harvey Bradshaw index – modified CAI
- Van Hees Index: objective index

Ulcerative Colitis:

- Truelove and Witts UC activity index

PATHOLOGYUlcerative colitis:

- no pathognomonic features – in extreme forms resembles CD
- *Neutrophilic infiltrate*
- *Goblet Cell mucin depletion*

Crohn's Disease:

- bystander bowel may have fistula – just repair that bowel if it is otherwise normal
- *mononuclear infiltrate*

	UC	CD
Early	Goblet cell Depletion	Minimal GC Depletion
Intermediate	Uniform Crypt Abscess	Focal Crypt Abscesses
	Neutrophilic infiltrate	Mononuclear infiltrate
Late	Neuronal Hyperplasia uncommon	Neuronal Hyperplasia common
	Dysplasia common	Dysplasia uncommon

Indeterminate Colitis:

- in 10-15% difficult to ascertain
- usually a rapid fulminant course, where UC is like CD
- “rectal sparing” may be just because of enemas

Serum Tests for IBD

- ESR and CRP only standard tests for now
- ANCA more often in UC but in 20-30% CD also
- ASCA: 50-70% CD, only 10-15% UC
- Gene mutation: NOD2/CARD15 in 10-30% CD pts

Evaluation of Acute IBD Patient

- Rule out a secondary disease:
 - pseudomembranous colitis
 - CMV colitis
 - fungal sepsis
 - neutropenic colitis/enteritis

40 Medical Mgmt of Inflammatory Bowel Disease**Medical Mgmt of Crohn's Disease**

Sx: Diagnosis usually in 2nd or 3rd decade

Induction Therapy for Crohn's DiseaseMild-Moderate Crohn's Disease

Sx: tolerate diet, ambulating, no signs of systemic toxicity

Rx: Aminosalicylates & antibiotics

- Topical Steroid: Budesonide

Sulfasalazine: a compound of sulfapyridine and 5-aminosalicylic acid (5-ASA AKA mesalamine)

- Azo- bonded: cleaved into active form by a colonic bacteria → so not effective in small bowel Crohn's
- 40-50% of pt's achieved clinical remission
- Dose Independent S.E: pneumonitis, hepatitis, pancreatitis, anemia, bone marrow suppression, reversible sperm abnormalities, impaired folate absorption
- All should receive daily folate (1 mg/day)
- New formulations to minimize side effects:
 - Pentasa: controlled release throughout SB & colon
 - Asacol: release in terminal ileum & cecum at pH 7

Antibiotics:

- alternative 1st line therapy in mild-moderate disease
- work better in colonic than small bowel disease
- metronidazole shown to efficacious, better effect to crossover to flagyl than from
 - Side effects: metallic taste, peripheral neuropathy (irreversible at time) – risked at >1 g/day
- Cipro 1 g/day – 50% remission shown
- Initial treatments show combo Cipro/flagyl best Rx

Budesonide:

- only FDA approved agent for ileum/right colon
- potent glucocorticoid, 1st pass metabolism – 90% in liver, so only 10% reaches system as a whole
- Rx: 8-12 wks 9 mg/day – high remission rate than mesalamine

Moderate-Severe Crohn's Disease

Sx: abdominal pain, >10% weight loss, n/v, anemia

Rx: steroids, infliximab, immunomodulator therapy

Corticosteroids: mainstay for mod-sev disease

- Prednisone 40-60 mg x8-12wks – remission in 50-70%
- not safe, nor effective for maintenance
- consider Budesonide and then switch to prednisone if fails
- 50% of pt's eventually become steroid dependent/resistant

Immunomodulators – Thiopurines:

- Azathioprine (AZA) 2-2.5 mg/kg qd
- 6-mercaptopurine (6-MP) 1-1.5 mg/kg qd
- need 3-4 months to achieve affect
- allow for better remission and steroid sparing

- monitor for *leukopenia* Q1-2 weeks and then Q3 months
- safe during pregnancy
- no risk for lymphoproliferative disorders (an old concern)

Methotrexate: IM or SQ – 25mg Qweeks

- steroid sparing agent
- mild increased LFTs
- leukopenia, pneumonitis possible but rare
- contraindicated in pregnancy; no alcohol while on this

Infliximab: chimeric monoclonal antibody to TNF

- induction and maintenance of Crohn's for those refractory to steroids and thiopurines
- reduces perianal fistula
- 5 mg/kg given at 0, 2 and 6 weeks as induction; then redoes every 8 weeks to maintain response in most and decrease rate of antibody formation to infliximab

Latent TB can be re-activated in these patients, so all should be screened with CXR

Severe-Fulminant Crohn's

Start with high dose IV steroids equivalent to 40-60 mg prednisone

If fail after 5-7 days, consider Infliximab, Cyclosporine, Tacrolimus

Mgmt of Perianal Crohn's Disease

1st line: drainage and antibiotics

2nd line: AZA, 6-MP, CSA, Tacrolimus

- steroids no role in perianal Crohn's

3rd line: Infliximab

- 68% improved, 55% fistulae ceased – avg time 12 weeks

Maintenance Therapy for Crohn's

1st line: Thiopurines prove to work (5-ASA no role here)

2nd line: infliximab – being researched, initial studies show works well

Indications for Surgery in Crohn's

Up to 2/3 need it at some point, though not curative for them

Disease predictably recurs at anastomosis

Any patient that fails intense inpatient care for 7-10 days should be considered a surgical candidate

Postop Prophylaxis for Crohn's Disease:

60-80% e/o recurrence on scope, 10-20% clinically

- smoking strongest predictive factor for recurrence

Diversion prevents recurrence

Medical Mgmt of Ulcerative ColitisInduction Therapy for UC

Sx: bloody diarrhea, rectal urgency, tenesmus

Histologic sign of remission: absence of neutrophils in the epithelial crypts

Treat only proctitis/distal disease differently than proximal/total colonic disease

- for total colonic disease, see Crohn's treatments

Mild: <4 BM per day

Mod: mixed b/n mild and severe

Severe: >6 BM per day

Fulminant: >10 BM /day

Mild-Moderate Proctitis

- suppositories should suffice

- Mesalamine 1-1.5 g/day (Canasa) good up to 20 cm disease

- respond by 2-3 weeks for most (some 4-6 wks)

- Systemic therapy rarely needed

Mild-Moderate Distal Colitis

1st line: Topical 5-ASA – nightly enema 4g/60 mL

(Rowasa)

- if no response by 2-4 weeks, add a morning enema

- add steroid enema in morning – Budesonide (Entocort)

Mild-Moderate Extensive UC

- need oral (systemic) therapy

1st line – 5-ASA or newer – follow same algorithm as in Crohn's

Severe UC

Admit, IV solucortef 300 mg daily (or solumedrol 48 mg)

Empiric antibiotics have no established role in treatment but most still give

CSA rescue therapy to force remission: side effects risks of seizures, hypomagnesemia. If fail after 7 days, operate on them.

Role of infliximab not defined in severe UC

Maintenance Therapy for UC

1st line: aminosalicylates

2nd line: AZA & 6-MP to keep people off steroids

- steroids not good for maintenance

5-ASA topical (enema) to maintain – then reduce frequency overtime from every night to every 3rd night

Steroid-Induced Remission in UC

Steroids not good for maintenance, however some patient become steroid dependent, and can not come off steroids or will immediately relapse – these patients should be considered for AZA or 6 MP treatment

- thiopurines slow to onset, so corticosteroids until at therapeutic levels

CSA-induced remission in UC

- transition to CSA PO

- transition to thiopurines

- PCP prophylaxis with Bactrim DS three times a week

- goal CSA at 150-300 ng/mL

41 Surgical Management of Ulcerative ColitisINDICATIONS FOR SURGERY

- Acute Flare refractory to medical therapy
- life-threatening complications
- medical intractability
- risk of malignancy: increase 1-2% after 8-10 yrs
 - 20% risk at 20 years
- disabling extracolonic disease
- growth retardation in children
 - rapid growth spurt often after surgery

Emergency Versus Elective ProceduresElective Options:

1. TPC and Brooke Ileostomy: optimal surgical approach
2. TPC and continent ileostomy:
3. TAC and IRA: 25% will require proctectomy eventually
4. TPC and IPAA: standard practice now

Emergent Options:

1. TAC with Brooke Ileostomy
2. Turnbull blow-hole – historical option
3. Proctectomy – not advised in emergency situation

Technical Aspects of subtotal colectomy:

1. mesenteric dissection at ICV should be flush with colon – preserves ileal branches of ileocolic vasc.
2. avoid mobilizing rectum in pelvis - go to promontory

BROOKE ILEOSTOMY

If does not reach:

1. may select more proximal portion of ileum
2. loop-end ileostomy may be better

Current indications:

- elderly patients
- distal rectal CA
- severely compromised anal function
- patient choice after proper education

CONTINENT ILEOSTOMY: - contraindicated in Crohn's Dz

Operative Technique

- run bowel to ensure no e/o CD
- terminal 45-60 cm of ileum
- aperistaltic reservoir via S-pouch
- 2 15-cm limbs of ileum sutured to form pouch
- distal mesentery taken of 15 cm distal limb
- intussusceptions secured with sutures and staples
- sutured flush with skin, can be lower than ostomy
- tube placed in early post op period, occluded for longer periods up to 10 hours when can be removed
- pouch intubated three times a day

Post op Complications

- nipple valve slippage (30% - MC), pouchitis (25%), obstruction (5%), fistula (10%)

Variant procedures: Barnett modification & T-Pouch

- no studies to prove they work better

ILEORECTAL ANASTOMOSIS

Indications: indeterminate colitis, High-risk, elder patients, mild rectal disease

Contraindications: disease rectum, dysplasia, perianal disease, compromised anal sphincter

Post op Course:

- 2-4 BM's per day (vs 6-8 for IPAA)
- IRA in UC -
 - Risk rectal CA: 6% - most between 15-20 yrs post
 - will need Q6 months flex sig w/ biopsies to survey
- recurrent inflammation in 20-45%
 - 1/3 will require proctectomy

ILEAL POUCH-ANAL ANASTOMOSIS

- must have good sphincter function
- topical 5-ASA & Steroid enemas may assist mucosectomy

Operative Technique

- explore to rule out CD

Technical Points:

- evidence to avoid omentectomy
- staple ileum flush with cecum
- preserve ileocolic artery and vein
- pouch limbs 15-25 cm each – decision based on reach
- if mucosectomy – 4 cm rectal cuff above dentate
- If pouch needs more length:
 - superficial incision on anterior and posterior aspects of small bowel mesentery along SMA
 - mobilize small bowel mesentery up to and anterior to the duodenum
 - selective division of mesenteric vessels to the apex of the pouch
 - S-Pouch can provide extra length, but more problems post op
- Post op:
 - check pouch for leaks, fistulas, sinus tracts, strictures
 - check anal sphincter tone
 - kegel exercises to increase tone prior to reversal
 - contrast and endoscopy
 - close ostomy at 6-8 weeks post

Post op Complications:

- SBO: 20%, infertility
- Pelvic Sepsis: 5%
- IPAA Stricture: 5-38%
- Anastomotic dehiscence: 10%
- Pouch Vaginal Fistula: 3-16%

Pouchitis (25%):

Sx: abdominal pain, fever, sudden increase in stool frequency; Chronic Pouchitis: suspect CD

Rx: Cipro and Flagyl

CONTROVERSIES

- 10% indeterminate colitis – work up & counsel
- Age should not be sole contraindication – elderly with LARs do well, so IPAA should be considered as well
- If stage IV CA avoid IPAA to not delay chemo-XRT
- Cecal CA in UC may prevent pouch due to oncologic Rsn

42 Surgery for Crohn's DiseaseETIOLOGY AND INCIDENCE

- considered environmental & genetic factors
 - 50-60% concordance with twins
 - chromosomes: 16q, 12, 6p, 14q, 5q, 19, 1p
- Incidence 7/100,000
- Male:Female 3:2
- Bimodal Age: 15-30 & 60-80

DISEASE CLASSIFICATION

Vienna Classification: age, location, behavior

- (1) Age at diagnosis: <40 or >40
 - (2) Location: TI, Colon, ileocolon, Upper GI
 - (3) Behavior: Inflammatory, Stricturing, penetrating
- >80% change class, so not too useful; clinicians subjectively disagree on a patient class as well

OPERATIVE INDICATIONSToxic Colitis:

- Disease Flare w/ 2 of the following:
 - hypoalbuminemia (<3)
 - leukocytosis (>10.5)
 - Tachy (>100)
 - temp (>38.6)
- first resusc patient unless abdominal catastrophe
- medical therapy first line: steroids, biologics, immunomodulators, empiric antibiotics
- if no improvement after 5-7 days, t/c surgery vs new medical therapy
- Surgical options:
 - Subtotal with end ileostomy – standard of care
 - TPC w/ end ileostomy
 - loop ileostomy w/ blowhole colostomy

Hemorrhage:

- endoscopy if can
- if not mesenteric angiography to identify site and treat
 - in CD – may be small bowel source
- after 6 units transfused, consider bowel resection

Perforation:

- typically at or just proximal to a stricture
- Rx: resection of involved bowel – anastomosis based on patient status – diversion safer

Neoplasia:

- RR 4-5x of small bowel & hepatobiliary cancers
- RR 2.6% colon CA (similar as UC)
- RR of rectal cancer not increased
- Plan: as in UC – start colonoscopy 8-10 yrs after onset
 - four quad biopsies every 10 cm
 - directed biopsies of strictures and lesions
 - repeat every 1-2 years

Growth Retardation:

- abnormal linear growth secondary to delayed skeletal maturation – improves after resection

Extraintestinal Manifestations:

- 25% of CR pts. Skin, mouth, eye, joints
- musculotcutaneous ones more likely to improve w/ op

OPERATIVE CONSIDERATIONS

- GI complications MC indication to operate
- many factors influence operative decisions
- ignore asymptomatic disease; CD incurable
- non-diseased bowel may be involved by fistulas/adhesions
- Mesenteric division can be difficult
- Resection margins should be conservative

OPERATIVE OPTIONS

Internal Bypass: not used as often anymore, but certain choice situations where it would still be efficacious

Fecal Diversion:

- deep ulcerations and high complex fistulas MC to fail diversion
- some times needs a secondary procedure to work – advancement flap, resection, ...

Strictureplasty:Indications:

- multiple strictures diffusely in SB
- stricture in pts w/ previous >100 cm SB resection
- rapid recurrence of CD w/ obstructive disease
- stricture in patient already with short bowel
- Nonphlegmonous fibrous stricture

Contraindications:

- perforation of bowel
- phlegmonous inflammation, any fistula involving site
- multiple strictures in short segment
- stricture close to resection margin
- albumin <2

Types:

- Heineki-Mikulicz: <10 cm
- Finney: 10-20 cm
- Jaboulay: > 20 cm – side to side internal bypass

Resection:

- secondarily involved bowel in internal fistulas that are otherwise normal – do wedge resection of fistula
- not recommended to attempt to remove enlarged LNs

SPECIFIC ANATOMIC LOCATIONS

Terminal Ileum: avoid too much resection (R Hemi) – increases chance for internal fistula to duodenum

Colon: segmental resections as per disease

- IRA: those w/ max tolerated rectal volume <150 ml do poorly with IRA

Upper GI: poor form of Crohn's – avoid resection and internal bypass, try to do strictureplasties

Anoperineum: ignore asymptomatic Dz, control sepsis

- infliximab at 0, 2 and 6 wks – 50% fistulas close
- more effective w/ cipro, and redoses Q8weeks

SPECIAL CIRCUMSTANCES

Intramesenteric Abscess: exclude the bowel – proximal and distal bypasses, drain abscess into the bowel and through the mucous fistulas; resect it in 6 months

Psoas Abscess: Resect bowel & externally drain abscess

43 Less –Common Benign Colorectal DisordersISCHEMIC COLITIS

Younger patients – risk factors:

- collagen vascular diseases
- hematologic disorders
- long distance running*
- cocaine abuse
- Many instances are self-limited
- Pain worse prognostic factor than melena

COLLAGEN VASCULAR-ASSOCIATED COLITIS

- immune complex deposition in vascular walls → ischemia/thrombosis

Polyarteritis Nodosa:

- systemic, necrotizing, small & medium arteries
- tends towards bifurcations & vessel branches
- Men, 40-60s
- many organs, non-specific abdominal pain
- mortality rate, when untreated – 50% in 1st 3 mo
- Rx: immunosuppression w/ corticosteroids
- *Churg-Strauss*: variant of PNA – eosinophilic infiltrate
- operate for abdominal catastrophes – diversion is key
- Arteriogram: saccular & fusiform aneurysms

Cryoglobulinemia:

- *cyroglobin*: immunoglobulin that undergo reversible precipitation at low temps
- associated w/ other disease, or idiopathic
- usually complicates other diseases
- GI problems rare but are ischemia & infarction

Henoch-Schönlein Purpura

- tissue deposits of immunoglobulin A containing immune complexes
- GI pains, arthralgias/it is, purpura, glomerulonephritis
- GI bleeding in 40%
- Intramural hematomas, intussusceptions, infarction & perforation are possible sequelae

Behçet's Syndrome

- chronic relapsing inflammatory, multisystem – widespread vasculitis small & large arteries & veins
- young Mediterranean & Japanese men; aggressive
- unknown path – genetic predisposition w/ environmental trigger
- GI involvement → poor prognosis; ileocecal MC
- ulceration from mouth to anus
- Similar to CD and UC, but no granuloma formation (as in CD)
- early surgery advocated to avoid catastrophe – divert

Systemic Lupus Erythematosus

- systemic, autoimmune, microvascular inflammation & autoantibodies; antinuclear antibodies
- GI involvement – 50% mortality: ulcer/infarc, hem, perf
- arteriography & CT not sensitive tests
- diagnosis often only after pathology
- Rx: corticosteroids and cyclophosphamides

Scleroderma

- multisystem, multistage, small arteries & conn. Tissue
- Women 20-40s
- GI symptoms may precede diagnosis by several years
- overproduction of collagen, increased humoral immunity, abnormal cellular immunity
- GI: Esophagus in 50%, SB/colon – chronic pseudoSBO
- Rx: prokinetics and antibiotics for bacterial overgrowth
 - Somatostatin for severe diarrhea, when seen
- Fecal incontinence & severe constipation common

Polymyositis:

- inflammatory muscle disease
- weakness, high levels of striated muscle enzymes, and e/p inflammatory myopathy
- symmetric muscle pain and weakness
- serum CK 5-50x normal – sensitive test
- Rx: steroids and immunosuppression
- GI symptoms – treat conservatively unless catastrophe

MICROSCOPIC COLITIS

- 10% of referrals for chronic diarrhea
- 50:50 collagenous vs. lymphocytic cause
 - lymphocytic diffuse
 - 10 lymphocytes per 100 epithelial cells
 - collagenous patchy
 - collagen deposits in *subepithelial layer*
- Most women in their 60's
- all chronic diarrhea patients should have biopsies – random & multiple
- Rx: diet modifications; stop NSAIDs, and then in order:
 - loperamid & diphenoxylate/atropine symptomatic
 - bismuth 524 QID x8wks
 - Cholestyramine induces remission
 - Steroids
 - Immunosuppression
 - fecal diversion

Eosinophilic Colitis:

- eosinophilic infiltration of tissues
- steroids for treatment
- surgery for complications

Fungal Colitis

- HIV, immunocompromised, steroids
- Candida, Histoplasma, Cryptococcus
- Fever, abd pain, diarrhea
- scope diagnostic
- nystatin 500,000 – 1,000,000 QID or, if sicker
 - ketoconazole 200-400 mg daily (or amphotericin B IV)
- surgery for complications

Histoplasmosis

- endemic in US Midwest
- in immunocompromised → ileocolitis → bleeding, ulcer stricture and perforation
- biopsy: intracellular budding yeast
- Ketoconazole (amphotericin B if fulminant)

Cryptococcus

- affects CNS – via inhalation of contaminated soil
- GI in immunocompromised – colitis w/ perf
- biopsy: encapsulated budding yeasts (or stool cx)
- ketoconazole (amphoB in critically ill)

BACTERIAL COLITIDES

- Watery diarrhea: supportive treatment
- *Dysentery*: bloody diarrhea, fever, abdominal pain – identify organism to give antibiotic

Escherichia Coli

- four classes of E. Coli infection
- (1) *Enteropathic*: severe diarrhea outbreaks in nursing homes. Self-limited, supportive therapy. Cytotoxin in small bowel causes mucosal damage. Bactrim
- (2) *Enterotoxigenic*: developing nations – *Traveler's diarrhea* – toxin produced does not damage mucosa but causes secretory diarrhea; Supportive treatment only. Prophylaxis with Bismuth 2 tabs QID, but avoid this in kids.
- (3) *Enteroinvasive*: shigella-like; mucosal invasion; self-limited. Supportive, but if dysentery Rx w/ Bactrim
- (4) *Enterohemorrhagic*: cytotoxin produces serious dysentery; undercooked meat; supportive treatment, no antibiotic for this. May lead to Hemolytic Uremic syndrome.

Shigella:

- *S. Sonnei* & *S. Flexneri* MC in US (2 others less common)
- produce dysentery – GNR toxin penetrates epithelium
- fecal-oral transmission
- *S. Dysenteriae*: in developing nations, worse course
- 10-100 BMs daily
- rectosigmoid most affected, but severe can be total
- Supportive, Bactrim, Cipro, Ampicillin until stool cultures negative

Salmonella

- GNR, two clinical conditions
- (1) *Typhoid Fever*: *S. Typhi* & *S. Paratyphi* – 3rd world
 - progressive, dysentery can lead to obstruction and perforation
- (2) *S. Enteritidis*: in US – self-limited gastroenteritis during warm months; contaminated food products; watery diarrhea to dysentery – usually SB infxn; Stool cultures & rectal swabs. Supportive care alone good, but if severe, pregnant or other – Bactrim also.

Campylobacter

- GNR – MC cause of acute diarrhea in US
 - *C. Jejuni* MC
- poor handling of chicken products;
- TI & Cecum MC – watery diarrhea to dysentery
- if mesenteric LAD may mimic Apy
- lasts 1 week to 3 weeks (usually less)
- Surgery rarely – supportive for most
- if antibiotics: Erythromycin or Cipro

Yersinia

- GN coccobacillus – gastroenteritis
- poor food handling, contaminated water
- invades peyer's patches in TI
- can mimic Apy
- Supportive therapy; critical Bactrim, cipro, tetras, amino

Tuberculosis

- immunocompromised
- via swallowing infected sputum or unpasteurized milk
- can cause fistulas and stenosis
- RLQ abdominal mass
- serology tests for intestinal disease 80% sensitive
- medical treatment for most – Isoniazid & Rifampin
 - some obstructions/fistulas resolve with medical Rx

Neisseria Gonorrhoea

- anal intercourse – oroanal spread
- often asymptomatic, may have anal discharge
- stool-free culture swab on Thayer Martin media
 - smear shows GN diplococci
- Ceftriaxone IM x1 or PO cefexime, cipro, ofloxacin

Syphilis

- *Treponema Pallidum* – anal receptive sex
- darkfield examination, immunofluorescent stains
- Penicillin G

Aeromonas

- related to host immunity status, age <2
- drinking untreated water
- watery stool, dysentery
- Quinolones, Bactrim, Tetras, Chloramphenicol
- endoscopy non-specific

Brucellosis

- *B. melitensis* – unpasteurized goat milk/cheese
- rare in US
- endoscopy: *protean* inflammation
- Doxycycline 100mg BID 3-6 weeks

Actinomycosis

- *A. Israelii* – anaerobic GP
- fistula tracts with *sulfur granules*
- ileocolic infection MC, but can be anywhere
 - Rx: resection of ileocolic infection
 - high dose Pen G 2-6 weeks

MISCELLANEOUS COLITIDESDiversion Colitis

- nonspecific inflammation of excluded colon
- deficiency of short chain fatty acids
- asymptomatic disease – no treatment
- symptomatic: irrigation w/ SCFA x 2-4 wks
 - steroid or 5-ASA enemas can also work

Neutropenic Enterocolitis

- predilection for TI & cecum;
- bowel rest, IV fluids, antibiotics, TPN
- surgery for perforation/peritonitis

Disinfectant Colitis

- from the disinfecting solutions to clean endoscopes
- *pseudolipomatosis* - lesions on bowel
- 24-48 hours later – abd pain, bloody diarrhea
- self-limited
- diligent rinsing of scope w/ forced air drying

Corrosive Colitis

- glutaraldehyd & formalin
- formalin enema to treat radiation proctitis
- pain, mucous diarrhea, rectal bleeding 48h post
- supportive treatment

NSAID and Salicylate-Induced Colitis

- discontinue
- 5-ASA and steroid medications

Toxic Epidermal Necrolysis

- AKA *Steven Johnson Syndrome*
- severe mucocutaneous exfoliative diseases; high mortality rate
- immune complex mediated
- Diffuse ulceration anywhere w/in the mucosal surface of the GI tract
- operate for perfs etc only

VIRAL COLITISCMV Colitis

- MC Viral cause of diarrhea, in culture (-) stool
- HIV w/ low CD4 counts
- abd pain to diarrhea to dysentery
- can lead to Toxic megacolon or perforation
- supportive treatment w/ retrovirals
- Dx: biopsy shows viral cytopathic effect in tissue*
- if you operate: Subtotal w/ end ileostomy (not segmental resections)

Herpes Simplex Colitis

- proctitis MC
- virus isolated in culture
- oral acyclovir
- rare perforations

PARASITIC COLITISAmebiasis

- *Entameba Histolytica*
- ingestion of cysts in food or water → invades intestinal mucosa
- many are asymptomatic
- symptomatic: abd pain, diarrhea, dysentery
- Dx: ELISA
- Rx: Flagyl + iodoquinol/paramomycin

Balantidiasis

- *Balantidium Coli* - tropical & subtropical regions
- pig is carriage organism – cysts in water & food
- dysentery
- Dx: trophozoites excreted in stool
- Rx: Tetracycline 500 mg QID x10days

Cryptosporidiosis

- HIV and immunocompromised patients
- voluminous watery diarrhea
- Dx: oocytes on fecal smears or colon biopsies
- Rx: Spiramycin & paramomycin

Giardiasis

- *Giardia Lamblia*; hikers and bikers – mountain lakes; adults caring for babies in diapers
- malabsorption
- Dx: trophozoites in stool or Giardia ELISA
 - negative stool exam not confirmatory
- Rx: Flagyl

Trypanosomiasis

- *Trypanosoma Cruzi* – Chagas' Disease
- Central America; Reduviid bug bite
- GI motility disorders and CHF
- Nifurtimox and benznidazole for acute phase
- Surgery for chronic: megacolon, constipation (severe)
 - Duhamel retrorectal abdominotransanal pull through
 - left hemi w/ colorectal anastomosis

Ascariasis

- large round worm *Ascaris Lumbricoides*
- ingest eggs – migrate from GI to portal to lungs, then coughed up and swallowed
- crampy abdominal pain, large worm load → SBO
- Dx: eggs in stool
- Rx: mebendazole/levamisole
 - surgery for perforation or unrelenting obstruction

Schistosomiasis

- fresh water, snail host
- *S. Japonicum*: SMV
 - associated with cancer
- *S. Mansoni*: IMV
- *S. Hematobium*: bladder, rectum, pelvic organs

Strongyloidiasis

- *S. Stercoralis* – nematode, soil-dwelling, rural southeast US; infects upper small intestine
- Sx: diarrhea, microcytic anemia
- Dx: stool aspirate *Stercoralis* larvae on wet mount
- Rx: Oral Thiabendazole 25 mg/kg Bid x 3 months

Trichuriasis

- Whipworm
- dysentery, TI and cecum MC infected
- barrel shaped eggs of *T. Trichiura* during stool exam
- Mebendazole 100 mg BID x3 days

Anisakiasis

- murine nematode in raw fish
- found in herin, mackerel, salmon, cod, halibut, sardine, squid
- invasion 1-5 days into stomach – abdominal pain
- mostly supportive therapy
- endoscopic removal provides cure

Tapeworm

- finding of ova in feces, undercooked meat
- *Diphyllobothrium Latum*: fish, B₁₂ deficiency
- *Taenia Solium*: pork, neurologic symptoms
- *T. Saginata*: beef,
- Rx for all: Niclosamid or praziquantel

AIDS Diarrhea

Tests: 3 stool samples & Colonoscopy w/ random bx's

- send stool for: fecal leukocytes, ova, parasites, acid fast bacteria, C. Diff, bacteria and fat stains

RADIATION-INDUCATED BOWEL INJURY

- Biphasic injury – acute and delayed
 - (1) Acute Injury: mucosal injury – mucositis, cramps, diarrhea; supportive treatment mostly
 - (2) Delayed injury: progressive obliterative arteritis & submucosal fibrosis → chronic ischemia of bowel
 - Proctitis: 4% formalin, ABG, Nd:YAG, Hyperbaric O₂
 - fistulizing: conservative measures
- Radiation tolerances:
 - 4500 cGy: 1-5% rate 5-year complications
 - 6500 cGy: 25-50%: rate 5-year
 - Rectum: 5500, 8000 for same rates

C. DIFFICILE COLITIS

Dx: stool culture, ELISA

Rx: vanco, flagyl, bacitracin

Surgery:

1. subtotal colectomy w/ end ileostomy
2. end ileostomy w/ mucous fistula

44 Intestinal Stomas

Ostomy: surgically created opening b/n hollow organ and either body surface or other hollow organ

To speak w/ Patient – Enterostomal Therapy (ET) Nurse, Wound Ostomy Care Nurse (WOCN) or *United Ostomy Association Visitor*

STOMA PHYSIOLOGY

- once >50 cm ileum lost → nutritional derangement

Output:

- more proximal ostomies, more liquid output
- Right Colon ostomy: liquid & smell of colon bacteria

Volume:

- normal: 1-2 L past ICV daily, down to 100-200 ml BM
- average ileostomy: 500-700 ml/day,
- too much ileostomy output: >1200-1500 ml/day

Transit:

- slower transit time increases absorption
- codein, loperimide and lomotil decreased transit time

Fluid and Electrolyte Balance:

- lose 2-3x more H₂O and Na⁺ than normal
- normal saline good for rehydration
- kidney decrease output by ~40% to compensate

Flora:

- Ileostomy: Staphy, Strepto, & Fungi
- B. Fragilis rare

Nutrition:

- colon little role on nutrition, more on fluid
- so colectomy little effect on nutrition
- TI loss can cause Vit B₁₂ def → megaloblastic anemia
- monthly injections to treat

PREOPERATIVE CONSIDERATIONS

- 5 cm radius ideal – from scars, ASCIS, umbilicus, belt
- avoid crevices
- if obese, may need to be supraumbilical for access

END OSTOMIES

- hernia preferable to ischemic ostomy – err bigger fascial hole
- 1-3 cm of mesentery can be stripped distally
- just remove disc of skin, not subQ fat – helps stoma stand up appropriately and not sag
- *Trephine*: vertical slit incision recommended over cruciate
- ileum to protrude 3-5 cm, colon 1-2 cm

Maturation:Ileostomy:

- not full thickness skin – possibility of implanation of mucosa cells into the skin → weeping patches & severe peristomal irritation
- 1-3 cm brooke advised
- 4 quadrant *Tripartite* seromuscular, mucosa & subcuticular

Colostomy:

- 1-2 cm protrusion or flat
- don't have to do seromuscular, but can

- can go through the skin

CONTROVERSIES

- subfascial sutures – some do it, no evidence
- mesh underlay – advocated to prevent parastomal hernias – no good studies
- Secondary maturation – in very sick patients with too much bowel wall edema – do on post op day 2-7
- Loop end ostomy for difficult to reach stomas
- *Lateral Mesenteric Closure*: very rare occurrence, not necessary to do this. Volvulus around fixed anterior attachment.
- *Extraperitoneal Colostomy*: colon mobilized and tunneled beneath the peritoneum

DIVERTING STOMAS

Indication: to divert fecal stream

Loop Ileostomy vs. Transverse Loop Colostomy

- loop ileostomy procedure of choice
- easier to make, better tolerated, same effluent as T-colon w/o as bad of a smell
- T-Loop: for all intensive purposes – historical
- larger lumens, don't stay everted, prolapse, in epigastrium, very malodorous

TURNBULL BLOWHOLE PROCEDURE

- indication: toxic megacolon in which the colon so dilated & tissue-paper thin that any attempt to perform an acute resection was likely to result in massive peritoneal contamination and death – a bridge before definitive resection
- Incision over dilated T-Colon – colon wall sutured to the peritoneum to prevent contamination, and colon edges sutured to skin
- Low midline incision to make a RLQ loop ileostomy

RESULTS OF STOMA CLOSURE

Most common complications: WI (9-34%), SBO (10%), fistula (<5%), leak (<3%). Long term hernias and SBOs 2-10%

- no difference in complication rates b/n stapled or hand-sewn anastomosis

MINIMALLY INVASIVE STOMAS

Trephine Stomas: only incision is stoma site – rarely done now b/c difficult to ensure right intestinal segment and limb of bowel.

Endoscopically Assisted Stoma: for left sided colostomies; FI, perianal sepsis, sacral decubs, diversion of anal surgery, hostile abdomen

TECHNICAL TIPS FOR DIFFICULT STOMAS

To obtain more length for left sided stomas:

1. division of lateral peritoneal reflection
2. mobilize splenic flexure
3. divide IMA at its takeoff
4. Divide IMV at take off below the pancreas
5. incision of splenic flexure mesentery

OSTOMY MANAGEMENT

- left sided colostomies can do irrigation to decrease overall bowel activity and allow better activity
- QOL scores higher with stoma than poor anorectal fxn

45 Stoma ComplicationsINCIDENCE:

Complications:

- loop ileostomy with most complications (75%)
- Descending end colostomy next most common (65%)
- Obesity associated with stoma necrosis

Risk Factors for complications:

- IBD, Obesity, Emergency Surgery, Diabetes
- Preop visit with ET nurse: Decreased morbidity rate

SKIN PROBLEMS:

Skin Irritation: more with ileostomy due to liquid, high alkaline, active enzymatic effluent

- upper abdominal stomas has less skin problems

After immediate post-operative period – edema and abdominal distention decrease, needing downsizing of appliance

Too frequent of changing can irritate the skin

Too infrequent of changing: erosion of protective barrier

Fungal Overgrowth: bright red rash around the stoma with associated satellite lesions. Rx: antifungal dusting powder

Allergic Reaction: dermatitis conforms precisely to the outline of the stoma appliance

Crohn's disease: no correlation with remote portion of the bowel and occurrence of pyoderma around the stoma

High-output Stoma:

Most often with ileostomy

- 5-20% of ileostomies in early post-op period

Ileostomy function by 3rd to 4th day, usually peaks on 4th

- rehydrate with sports drinks
- ileal resection removes "Ileal brake" – slows gastric emptying and small bowel transit

Nephrolithiasis:

- loss of sodium, water and bicarb → decreased urinary pH
- 4% gen pop incidences, 8% in ileostomy subgroup
 - 60% will be uric acid (10% in gen pop)
 - also increased rate of calcium oxalate stones
- avoid foods high in oxalate (eg spinach)

Bowel Obstruction

- 23% rate in ostomy patients
- red rubber irrigation of ostomy may clear food content bolus

Ischemia

- can evaluate with glass test tube or endoscope
- if viable at fascial level, then observe
- if not viable at fascia – emergency reop

Late Hemorrhage

- heavy bleeding (MC ileostomy) by portal HTN and stoma varicies development.
- ostomy revision does not prevent recurrence
- Treatment of portal HTN is key
- no standard algorithm as of yet

Stoma Closure:

- two randomized trials comparing stapled vs. handsewn
- risk of post op obstruction significantly high in the handsewn group
 - LOS equal between both
 - time to return of first flatus sooner with stapled
 - stapled lower risk of infection

Parastomal Hernia:

1. Site of stoma related to rectus: 6 studies found that no difference if through or lateral to rectus M.
2. Size of Abdominal Aperature:
3. Mesh Sublay: Have been found to preven hernation, however increased risk of stomal stenosis, erosion and infection with the mesh
4. Trans- vs. Extra-peritoneal tunneling:
5. fixation of stoma to abdominal fascia:
6. Repair of stoma: can resite, fix fascia to ostomy or apply mesh. Mesh higher infection, fixation high rate of recurrence.

46 Incontinence

Fecal Incontinence: inability to control feces and to expel it at a proper time

Mechanism:

- Rectosigmoid: antiperistaltic motion
- rectal capacity – acts as a reservoir
- CNS input necessary
- pelvic floor to keep sphincters tight

Soilage: continuous or intermittent liquid anal discharge

Pseudoincontinence (encopresis): involuntary loss of formed, semiformed or liquid stool associated with functional constipation as a child

Urgency: need to defecate immediately at the risk of incontinence when facilities are absent

- seen with impaired rectal compliance

Incontinence scores: Most widely used – Vaisey and Wexner

FIQOL – severity index and quality indicator by ASCRS

- best was to get info on incontinence

CAUSES OF INCONTINENCE

Congenital:

- hx of high anorectal malformation – severely defective fecal continence and poor quality of life
- 75% get voluntary control, 40% occasional soiling
- constipation frequent

Pelvic Floor Denervation:

- Pudendal nerves and S3/4 branches of pelvic plexus
- irreversible injury w/ as low as 12% stretch

Obstetric:

- 0.6 – 9%
- occult injuries seen on ERUS in 20-35%
- Risk Factors: forceps, mediolateral episiotomy, primiparity
- 60% will have concomitant pudendal nerve injury
- Traction injury to nerves also possible

Iatrogenic:

- Park's anal retractor MC – damage to internal sphincter from excessive dilatation
- sphincter division, rectal resection, neo-adjuvant therapy

Traumatic:

- uncommon cause of fecal incontinence
- immediate recognition is vital to a successful outcome and may prevent need for stoma
- anal intercourse associated with reduced resting pressure in the anal canal and an increased risk of anal incontinence

Radiation:

- 75% will have acute phase reactions
- 20% late-phase radiation proctitis

Physical Exam:

- Purborectalis: can be palpated bilaterally and posteriorly as a prominent sling passing around the rectum thus creating the anorectal angle that is normally 90 degrees

Anal Manometry:

- Checks: anal pressure, anal squeeze pressure, recto-anal inhibitory reflex, compliance of the rectum, sensory thresholds in response to balloon dilatation
- resting pressure: internal sphincter fxn
- Squeeze Pressure: external sphincter pressure
- no absolute numbers – can have normal numbers and have problems, or vice versa

Defecography:

- radiologic visualization of the act of defecation.
- demonstrates presence of internal rectal intussusception in patients with perineal symptoms or the solitary rectal ulcer syndrome

Endosonography:

- 7 to 10 MHz
- 3D improves ability for novice, but does not add anything to work-up

MRI:

- endo-coil in the anus with surface phased array coil
- coil is 2 cm so causes stretching of the sphincter
- MRI without the endocoil but with a phased array coil gives a view of that natural contracted sphincter.

Pudendal Nerve Latency Time:

- measures the time from an electrical stimulus of the pudendal nerve to the onset of the electrical response in the muscles of the pelvic floor.
- use finger electrode mounted on a glove
- prolonged latency is taken as evidence of neuropathy

Sensation Test:

- The sensitivity of the rectum is studied with inflation of an intrarectal balloon. The minimal volume that is sensed, the first urge sensation, and the maximal tolerable volume are determined. A high threshold of the minimal volume sensed in the rectum is abnormal (usually >20 mL)

Endoscopy: limited value, can exclude some diseases

TREATMENT OF FECAL INCONTINENCE

Conservative:

- meds to achieve 1-2 well-formed stools per day
- pads only appropriate for minor symptoms
- *Enopresis*: evacuate rectum and then proper habits
- Enemas to keep the rectum empty
- Bulking agents

Biofeedback:

- improves the threshold of rectal sensation and coordinates pelvic floor contraction with rectal distention
- must have: rectal sensation, ability to contract pelvic floor, motivation
- Mechanism of action not fully understood
- allows patient to better understand Nervous system of pelvic floor
- 75% with improvement, only 50% cure

Balloon Training: to increase sensibility of rectumElectrostimulation: not clinically effective for anal incont.Anal Encirclement: Same as Thiersch procedure for prolapse. High complication rate. No longer considered a viable option. Colostomy better than thisAnterior Sphincteroplasty: for anterior defects

- rectovaginal fistula is not a contra-indication
- may need temporary diversion
- Prone Jack knife, full bowel prep; injxn adrenaline solution, scare tissue dissected to level of anorectal ring, scar preserved to place sutures in, muscles overlapped with mattress sutures.
- Should not go over 180 degrees lateral to prevent nerve damage
- No packing, central portion left open to drain
- 50-80% fxnl outcome good

Postanal Repair:

- indication: denervation damage to pelvic floor
- Purpose: restore anorectal angle & length anal canal
- dissection through intersphincteric plain to levator plate
- low success rate (30-40%), but low morbidity and zero mortality

Sacral Nerve Stimulation:

- stimulate S3 – test for three weeks prior with diary
- implant lasts about 8 years, lower abdominal wall or buttocks
- best indication: intact sphincters, or prior failed repair
- good for neurogenic incontinence

Dynamic Graciloplasty:

- for long gap defects or complete destruction
- gracilis is auxiliary muscle for adductor muscles
- Minority of type one fibers (long acting, slow twitch) and a majority of type II (short acting, fast twitch) make it a poor substitute
 - with long term training, can be converted to type I
- implantable stimulator to stimulate it.

Artificial Bowel Sphincter:

- implantable fluid-filled, silicone elastomer cuff.
- inflated compresses the anus
- erosion of material is common complication

Colostomy:

- last alternative, after counseling
- because of mucous discharge, should also perform rectosigmoid resection with 3-4 cm cuff remaining to prevent mucous discharge.
-

47 Rectal Prolapse

Rectal Prolapse: circumferential intussusceptions of the rectum

- W > M; men affected younger and due to other dz

Patient Evaluation:

Sx: constipation, straining, incontinence, erratic BMs

- Squatting or sitting may elicit prolapsed

Mucosal Prolapse: radially oriented grooves

Full thickness prolapsed: concentric rings

Digital Exam – look for:

- concomitant anal pathology
- assess resting tone
- assess squeeze pressure
- assess function of puborectalis muscle
- Colonoscopy/FlexSig: to eval for mucosal abnormality
- Defecography: indicated to evaluate internal prociencia
 - not necessary in the evaluation of full thickness

Anal Manometry: to assess sphincter function

Colonic Transit Studies: if have hx suggesting problem

Surgical Procedures

Perineal vs. abdominal

- Men at risk sex dysfxn with abdominal approach
- High risk patients with perineal approaches

Most commons:

Abdominal: rectopexy w/ or w/o resection

Perineal: Delorme or Altemeier

Indications by symptoms:

- Constipated: resection and rectopexy
- Incontinent: abdominal rectopexy or Altemeier + levatorplasty

PERINEAL PROCEDURES**Perineal Rectosigmoidectomy – Altemeier**

- under general, spinal or MAC
- Prone position preferred
- rectal wall injected w/ epi compound for hemostasis
- circumferential incision into rectal wall 1-2 from dentate line
- deepened through full thickness of rectal wall
- once full thickness through, ligate mesorectum
- Anteriorly will encounter hernia sac
- dissect until no further redundancy
- hand sutured coloanal anastomosis
- if poor continence, levator placcation (works in 2/3)
- Morbidity: 5 – 24%
- Recurrence: 0 – 50%
- Mortality: 0 – 6%

Mucosal Proctectomy – Delorme

- ideal for full thickness limited to partial circumference or less extensive prolapsed
- only mucosa and submucosa excised
- general, spinal or local (MAC)
- 1 cm from dentate, incise through mucosa only
- Recurrence: 7-26%

Anal Encirclement - Thiersch Procedure

- Silver wire around the anus under local
- prone position
- local applied
- tunneling around anus, above anoperineal ligament
 - above anococcygeal ligament, as well
 - around external sphincter
- does not fix prolapsed, just traps it above
- only used if very six patients
- morbidity up to 60%
- recurrence up to 44%

ABDOMINAL PROCEDURES**Abdominal Rectopexy & Sigmoid Colectomy**

Four Essential Steps:

1. complete mobilization of rectum down to levator
 - MUST leave lateral stalks intact
2. Elevation of rectum cephalad with suture fixation of lateral rectal stalks to presacral fascia just below sacral promontory
3. Suture of the endopelvic fascia anteriorly to obliterate the cul-de-sac
 - modern days, many omit this
4. Sigmoid colectomy with anastomosis

Recurrence: 0 – 9%, Mortality: 0 – 7%, Morbidity: 0 – 23%

Abdominal Rectopexy (R,M: 3.6,1.4%)

- if don't also have constipation, can do this alone
- suture with prolene or other non-absorbable

Ripstein Procedure (R,M: 8,28%)

- currently seldom used
- 5 cm prosthetic mesh used to make a sling and anchor the rectum in place 5 cm below the sacral promontory

Ivalon Sponge (Posterior Wrap)

- most popular procedure in UK
- Polyvinyl alcohol sponge wrap around ¾ of rectum
 - anterior rectum not covered
- peritoneum closed over the sponge

Laparoscopic Rectopexy

- depending on skill, equivalent results
- hospital stay shorter in lap group

RECURRENT PROLAPSE

- must figure out prior procedure so you can determine the blood supply to the rectum, success in 85-100%
- no specific algorithm for treatment

Prior procedure and options for Redo:

1. Altemeir: Redo Altemeier, Abd Recto w/o Rsnx
2. Abd. Rect: Redo w/ poss Rsnx or Perineal
3. Abd Rect w/ Rsnx: Redo abd Rect – *avoid* perineals

SOLITARY RECTAL ULCER SYNDROME & COLITIS CYSTICAPROFUNDA

Solitary Rectal Ulcer Syndrome (SRUS): rectal bleeding, copious mucous discharge, anorectal pain, difficult evacuation

- can have single, multiple or no ulcers
- ulcers usually on anterior rectal wall just above anorectal ring
 - can occur just above to 15 cm from dentate (less frequent)
- ulcers usually "punched out" gray-white base surrounded by hyperemia

Cystica Profunda (CCF): benign; mucin-filled cysts located deep to muscularis mucosae.

- more frequent in colon and rectum (can be anywhere)
 - if in colon rectum Colitis cystica profunda
- usually on anterior wall
- asymptomatic or rectal bleeding, mucous discharge, anorectal pain
- must differentiate from CA since is benign

In both: 45-80% have intussusceptions

Differential: polyps, endometriosis, inflammatory, infectious, drug induced colitis, adenoCA

Endoscopic biopsies to differentiate

- In CCF: mucous cysts lined by normal columnar epithelium located deep to the muscularis mucosae

If no prolapsed, can do biofeedback

- not too many medical therapies that work
- surgical therapy for good candidates
- if no prolapsed, transanal excision may be possible

48 Constipation

Rome Criteria: for diagnosis, need 2 for at least 3 mo's

1. Straining > 25% of the time
2. Hard stool >25% of time
3. Incomplete Evacuation >25% of time
4. Two or fewer BM's per week

Mean colonic Transit times:

- Males: 31 hours
- Female: 39 hours
- small bowel transit: 90 – 120 minutes

Ex:

- Prevalance 2%
- F > M, increases with age
- Non-whites more often

Px:

- Medical conditions – hypothyroid, lupus, DM, Scleroderma, neurologic, immobilization, psych

Evaluation:

HPI:

- Details: stool size, frequency, consistency, ease & efficacy of evacuation
- age of onset, diet & exercise, meds, PSHx, PMHx
- hx of sexual abuse, psych illness
- urinary incontinence or related

- Patient diary: dietary intake, defecation frequency, stool consistency, associated symptoms

PE: usually unremarkable

Dx:

- 1st step always scope (or BE) to rule out obstruction
- If normal, then proceed:

Colonic Transit Time:

- estimated w/ marker study or scintigraphy
- *Marker Study*: refrain from all laxatives/enemas 2 days before study. Injest 24 radioopaque markers. Must ingest 30 g of fiber daily during the test, no lax/enemas. AXR on day 5.
 - 80% of normal patients will pass all markers by day 5
 - markers accumulated in rectum – outlet obstruction
 - distributed throughout – colonic inertia
 - more than 20% of markers remain – colonic inertia
- *More precise marker study*: ingest radiopaque marker for 3 days, then imaging on days 4 & 7.
 - <65 hours colonic transit time in 95% men
 - <75 hours colonic transit time in 95% women

Defecography:

- visualization of mechanism of defecation
- identify non-relaxing puborectalis or a rectocele

Anal Manometry:

- shows lack of rectoanal inhibitory reflex – suggests Hirschsprung's Dz
- Balloon expulsion testing can show outlet obstruction and add to reliability of defecography

Anal Electromyography:

- used w/ manometry – the recruitment of Puborectalis fibers during defecation simulation indicates a nonrelaxing puborectalis as cause of outlet obstruction

Lactulose Hydrogen Breath Test:

- evaluation of small bowel transit
- lactulose fermentation only occurs in colon.
- Record the time of ingestion of lactulose to time of production of Hydrogen to infer transit time

Medical Treatment of Constipation

- does not have to be one daily
- ensure no malignancy or other mechanical blockage
- increase physical activity and fluid intake

Bulking Agents: fiber, hydrophilic, facilitate absorption and retention of fluid.

- Synthetic methylcellulose derivatives
- SE: bloating, flatulence
- 20-30 g daily recommended

Osmotic Laxative: promote fluid mov't into colon

- derived from sugars/salts
- eg; Sorbitol/Lactulose – yield hydrogen, CO₂
 - Caution w/ these gases can cause explosion
- Milk of mag, Fleets, PEG

Colonic Irritants: stimulate colonic motility

- senna, cascara, bisacodyl,
- **Pseudomelanosis Coli:** from long term use, brown discoloration to mucosa of colon

Mineral Oil & Colace: manipulation of the composition of stool. Mineral oil coats stool, prevents absorption.

Colace decreases stool surface tension allowing more water into it.

COLONIC INERTIA:

- small % of constipated have this
- Total abd colectomy w/ ileorectal anast only if colonic transit only. Full work up before TAC
- if also have pelvic floor problem, 50% dissatisfaction with operative intervention

IRRITABLE BOWEL SYNDROME

- abd pain & bad BMs w/o identifiable path
 - can also have diarrhea
- Risk factor for psych illness
- myoelectric studies – suggest problem – shorter intervals b/n mmc's
 - Diarrhea: irregular short spikes
 - Constipation: irregular long spike bursts
- *Visceral Hyperalgesia:* increased sense of gut distention

Rome Criteria for IBS:

- Abd pain that is: improved after pooping, change in frequency associated, change in stool quality
- At least 2 of below >25% of time:
 - altered stool frequency
 - altered stool form
 - altered stool passage
 - Mucorrhea
 - Abdominal bloating/distention

Treatment of Diarrhea Predominant IBS:

- Anticholinergics: dicyclomine hydrochloride (Bentyl) and Hyocycamine sulfate (Levsin)
- Nonabsorbable synthetic opioids: Lomotil/Immodium
- Tricyclic antidepressants: amitriptyline (Elavil) & imipramine (Tofranil)

- Serotonin Agonist: alosetron (Ilotronex)

Treatment of Constipation Predominant IBS:

- fiber, osmotic laxatives
- serotonic agonist – Tegaserod
- Fedotazine

49 Pelvic Floor DisordersRECTOCELE

Abnormal rectovaginal anatomy allows rectum direct contact to vaginal serosa

- Almost exclusive to women, mostly vaginally parous

Normal anatomy: distal- most posterior vaginal wall 3 cm from the hymen. In rectocele this is decreased/lost

Physical exam may give different measurements

- prone will show most
- standing straining technique makes most pronounced

Gyn surgeons: focus on fixing vaginal apex – secondarily fixes rectocele

Isolated rectoceles rare – usually associated pathology

Sx: stool trapping, difficulty stooling, vaginal protrusion from posterior wall, should be painless

- if with pain, entertain other diagnosis
- if no major life issues, fix stool quality & biofeedback

Surgery benefits some symptoms, not all

- will fix abnormal anatomy, less successful at having to use hand to help

Preop testing before surgery:

- Colonoscopy
- Pudendal nerve testing has NO role
- Defecography to eval PRM

Pudendal Neuralgia

- symptom complex manifest by chronic pelvic/perineal pain in distribution of one or both pudendal nerves

Px: compression or entrapment of the pudendal nerve, positional in nature; usually in setting of prior trauma or cyclist or rowers

- sites of entrapment:

1. b/n sacrotuberous and sacrospinous ligaments
2. in pudendal canal (Alcock's Canal)

- may be due to hypertrophy of muscles during sports

Dx: reproduction of the pain with pressure on ischial spine; not very sensitive test

- PNLT: often delayed

- can perform nerve block to eval if nerve lysis would work – if nerve block works, consider neurolysis

Path of the pudendal Nerve:

- Arises from S2,3,4 – leaves pelvis beneath the piriformis muscle via greater sciatic foramen – then passes to sacrospinous ligament medial to the ischial spine and re-enters pelvic cavity
- runs ventrally to Alcock's Canal
- gives off 2 branches: inferior rectal & perineal

PELVIC PAIN SYNDROMESLevator Syndrome

Pain/pressure/discomfort in region of the rectum, sacrum & coccyx that may be associated with pain in the gluteal region & thighs

Diagnosis of exclusion

Rx:

- Digital Massage: daily 5-6d or once a week for 2-3 wks
- combine w/ heat and diazepam
- 68% reported improvement
- Transanal Injxn Trimecainolone: 37% success
- Biofeedback: 37% success
- treat anxiety and depression

Coccygodynia

distinct pain evoked w/ pressure or manipulation of coccyx

- associated with sacral tumors, trauma, avascular necrosis or lumbar disc referred pain

Steroid Injection: methylprednisone w/ manipulation under EUA

If fails, then coccygectomy

Proctalgia Fugax:

- fleeting pain in the area of the rectum lasting for a few minutes
- assumed from spasm of the rectum or pelvic floor
- once per year to 6 times per year

Rx: reassure patient not a serious disorder, can treat like a fissure (eg nifedipine)

51 Pediatric: Hirschsprung's and others ConditionsHIRSCHSPRUNG'S DISEASE

- fxnl colonic obstruction via absence of ganglion cells
 - deletion in long arm chromosome 10
 - absence of ganglion cells in:
 - (1) Auerbach's Plexus: b/n circular & longitudinal layer
 - (2) Henle's Plexus: in submucosa,
 - (3) Meissner's plexus: in superficial submucosa
- length variable, MC rectum and sigmoid
- *Enterocolitis*: from poorly understood immunologic mucosal defect
- Sx: usually w/in 48 of life – delayed meconium, distention, vomiting – DRE may cause explosive passage of stool and gas and ameliorate symptoms
 - if not treated promptly → sepsis, shock, perforation ...
 - *Encopresis*: overflow pseudoincontinence – from being overly constipated
- Contrast Enema: Dilated colon to point of aganglionosis
 - may not be evident in early neonatal period
- Manometry: absent anorectal inhibitory reflex (not reliable in neonatal period, more for adolescent disease)
- Histopathologic diagnosis – gold standard – absence of ganglion cells and present of hypertrophic nerves in rectal biopsy. Specimen must include *mucosa and submucosa*.
 - can also determine the *activity of acetylcholinesterase*

Medical Mgmt:

- until definitive surgery – colonic *irrigation* – to pass stool --- enemas is wrong answer, will not pass

Surgical Mgmt:

- one or two stage method based on training & patient
- different methods described:
 - *Swenson*: normal bowel to rectum above dentate
 - *Duhamel*: divide colon at peritoneal reflection, normal colon anastomosed to posterior rectal wall (in order to reduce risk of injury to pelvic nerves)
 - *Soave*: normal colon through muscular cuff of rectum. Anorectal dissection was submucosal above dentate.
- recommended to go 4 cm above the transition zone
 - biopsies and frozen section to experienced pathologist
 - if no experienced pathologist in acute setting, do right sided colostomy or ileostomy to be safe

Surgical Mgmt of Total Colonic Aganglionosis

- No good mgmt plan has been found
 - Author advocates: TAC w/ IRA
 - Others: TPC w/ IPAA, TPC w/ Duhamel, leave right colon as neorectum, ...
- poor quality of life with all options
 - patient develop secretory diarrheas – difficult to mgmt

Surgical Mgmt of Ultrashort Disease

- controversial diagnosis, since aganglionosis is normal above dentate, just distance has not been defined

- posterior midline internal sphincterotomy up to 15 cm above the dentate line (start 1 cm proximal to it) – use a posterior sagittal approach (Kraske)

Neuronal Intestinal Dysplasia

- diagnosis of exclusion – for patients that have failed operations for Hirschsprung's disease – essentially grab back of abnormalities
- pathologists don't agree on this diagnosis
- no treatment strategies

MEDICAL MGMT OF FECAL INCONTINENCE

- bowel mgmt program to keep colon clean of stool and make them socially acceptable
 - daily enema or colon irrigation
 - trial an error, every mgmt plan different
 - *Malone Procedure*: continent appendicostomy – appendix attached to umbilicus for antegrade enemas. Allows independence

Relevant Aspects when these patient become adults:

Group 1: poor sacrum, flat perineum, poor muscles, no sensation, incontinent of urine and feces; unlikely you can help them. Do bowel mgmt program or permanent stoma.

Group 2: mislocated rectum – good sacrum and good muscles; do redo PSARP w/ Pena stimulator

Group 3: severe constipation w/ severely dilated mega rectosigmoid; Do sigmoid resection.

Group 4: patients w/ good muscles, rectum in right place, good sacrum. Benefit from biofeedback training.

OTHER PEDIATRIC COLORECTAL DISORDERSIdiopathic Constipation

- vicious cycle of colon enlarging, less functional
- chronic fecal impaction → encopresis
- unknown cause, laxative important for relief
- Surgery: rectosigmoid rxn (remove all dilated)
 - does not cure, but improves

Rectal Prolapse:

- due to myelomeningocele, spina bifida, ...
- altemeir's or rectopexy +/- sigmoid rxn

Perianal Fistula:

- fistula common but different condition than seen in adults
- almost all spontaneously heal by a year
- Rx of abscess – most drain spontaneously, if not simple I&D, antibiotics not necessary
- may recur, but eventually, almost all heal
- THM: do NOT do fistulotomy in kids

Juvenile Polyps:

- at ~ 4yrs benign polyps in rectum and colon
- self amputate and disappear
- most in posterior rectal wall, long pedicle
- Sx: blood surrounding stool in toilet
- biopsy one to ensure benign

Anal Fissure

- consequence of constipation
- laxatives to make soft stools pass until fissure heals, or else child holds in stool, making it harder and makes vicious cycle
- 2% NTG (glyceryl trinitrate) ointment efficacious in kids

ANORECTAL MALFORMATIONS

- *Cloacal Malformation*: rectum, vagina, urethra fused
- associated urologic malformations in most (>50%)
 - Unilateral Renal Agenesis MC malformation
 - Vesicoureteral Reflex 2nd most common
 - sacral and spinal abnormalities are common – worse sacral & spine correlate with poor fxnl outcomes
- *Tethered Cord*: in 25% - cord is abnormally tethered to spine – predicts poor outcome – poor sphincter fxn
- *Currarino Triad*: anorectal malform, hemisacrum & pre-sacral mass – have very poor fxnl prognosis
 - MC masses: teratoma, dermoid, lipoma, meningocele, or combo of them
- *Esophageal Atresia*: in 8% - usually very high defect
- *Cardiovascular Anomaly*: in 30% - PDA, ASD, VSD, TF
- The higher the malformation, the worse the functional prognosis will be
 - higher: more have FI, less constipation, flat perineum
 - Lower: more likely constipated, less FI

DESCRIPTION OF SPECIFIC ANORECTAL DEFECTS:

Perineal Fistula: simplest; rectum opens into anterior perineum; most have normal sacrum, <10% associated defect; fxnl prognosis good. Move orifice back to center of sphincter

Rectourethral Fistula (males): rectum → urethra; Bulbar (low) vs. Prostatic (High)

- Bulbar: most good fxn, 30% associated anomaly
- Prostatic: poor fxn, 60% associated anomaly
 - bifid scrotum more likely
- most will be diverted shortly after birth, repair 1 mo

Vestibular Fistula (Females):

- MC in defect in females; 30% associated anomaly
- rectum → vestibule just outside hymen
- good fxn in most postop, sacrum usually normal
- PSARP

Rectobladder Neck Fistula:

- highest defect; 90% associated anomaly; flat perineum
- laparotomy and PSARP
- only 15% achieve bowel function

Imperforate Anus Without Fistula:

- 50% have Down's, 90% of Down's that have anorectal problem have this
- have good sphincters and sacrum – good fxn p repair

Rectal Atresia

- failure for canalization – sphincter and sacrum fully normal

- 100% of babies regain normal fxn post op

Cloaca (Female)

- rectum, vagina and urinary tract fused
- open in normal place of urethra
- length of channel related to prognosis – *longer: worse*
 - 3 cm is critical length
 - <3 cm – can repair via posterior sagittal approach
 - >3 cm – difficult, needs abdominal approach, need GU specialist, 90% w/ associated anomaly
- *Hydrocolpos*: in 40% - dilated, fluid filled vagina
- *Vaginal & Uterine Septations*: 40% - impacts menstrual flow, fertility

Rectovaginal Fistula: extremely rare – usually vestibular – fix with PSARP

INITIAL MANAGEMENT – ANORECTAL MALFORMATIONS:

- Most imaging should be done at 24-36 hours to allow rectum to descend and see if meconium passes
 - While waiting 24 hours – ensure safe to wait
- Get Echo, Spinal Images, PXR, Ultrasound of abdomen (kidneys), NPO, NGT
- If can't do repair, do diverting colostomy
- in females, if cloaca you MUST rule out hydrocolpos – it can cause renal obstruction. If so, drain it.

Colostomy:

- should be totally diverting – not loop
- double barrel left colon
- mucous fistula should have enough length to allow for pull through when definitive surgery performed so stoma not in the way
- Hydrocolpos can be drained transabdominally via vaginotomy to abdominal wall if big enough or drain
- *high pressure distal colostogram*: 2 weeks post ostomy
 - most important to figure out anatomy

MAIN REPAIR

Perineal Fistulas:

- relocate the anus back in b/n sphincters
- Must have foley – DO NOT injure urethra
- *Cutback*: posterior cut of fistula to make wider and allow drainage
- Emergency: can simply dilate to allow stool to pass

Rectourethral Fistulas:

- posterior sagittal anorectoplasty
 - posterior sagittal incision midline to base of scrotum
 - leave sphincter equal amount on both sides
 - posterior rectal wall identified and dissected circumferentially
 - sutures placed in rectum to assist with traction
 - dissect 1 cm proximal to allow mobilization

Rectobladder Neck Fistula:

- Laparotomy in addition to PSARP

Vestibular Fistula

- key technical challenge is separation from vagina – usually have one fused wall that must be evenly divided into two

Cloaca < 3 cm:

- PSARP + Total Urogenital Mobilization

Cloaca > 3cm: refer to specialized center – will need combined approach with specialized urologist

54 Critically Reviewing LiteratureSTUDY DESIGNS – (IN ORDER OF STRENGTH)Case Series:

- Report < 10 patient, series > 10 patients (arbitrary #)
- no control group (maybe a historical one)
- retrospective review
- least power, but still important for observation of outcomes to guide stronger studies
- RCTs confirm observations from series
- selection, referral biases;

Case Control Series:

- to study risk factor or causation
- control group has selection bias (not randomized)
- retrospective review
- outcome is present at start of study

Cohort Studies:

- retrospective or prospective
- two groups, not randomized
- outcome is NOT present at start of study
- bias due to non-randomization

Randomized Control Trials (RCT):

- best trial design to evaluate a treatment
- random allocation to one of two groups
- intervention & follow up standardized
- prospective follow up
 - limits differences from unknown factors
- Limits: take a long time, expensive, results may not be generalizable, sometimes not feasible (rare diseases)

LEVELS OF EVIDENCEASCRS Standards Committee Level/Grade Recs:

Level I: evidence from a metaanalysis of multiple, well-designed controlled studies. RCTs w/ low false-positive & low False-Negative errors (high power)

Level II: evidence from at least one well-designed experimental study. RCT w/ high false-positive and/or false-negative errors (low power)

Level III: evidence from nonrandomized, controlled, single-group, pre-post, cohort, time, or matched case-control series

Level IV: evidence from well designed case series

Level V: evidence from case reports & clinical examples

Grade A: Type I evidence or multiple II, III or IV

Grade B: generally consistent II, III or IV

Grade C: evidence of types II, III or IV but not consistent

Grade D: little or no systemic empirical evidence

SYSTEMATIC REVIEWS OR METAANALYSES

- Both have an explicit, specific question they are asking
- Systematic Review: qualitative
- Metaanalysis: statistical method
 - study results combined to make a conclusion
 - useful when studies seem to differ in conclusion
 - when study are too small or would be too costly

- likely to omit “negative” trials – not published because didn’t show a difference
- should try to only do with RCTs

Charlson Index:

- for risk adjustment
- predicts the risk of dying by assigning a score to each comorbidity

Quality of Life

- survey should have reliability, validity, responsiveness
- reliability: how often will it give same results if measuring same population
- validity – 3 types (accuracy):
 - Criterion: measured against a gold standard
 - content: how well the entire spectrum w/in a scale is covered
 - construct: how well it measures unobservable phenomenon
- Responsiveness: sensitivity to change – ability to detect true differences

Ileoanal Pouch Procedure for UC & FAPIndications:

- Ulcerative Colitis: principle indication
- Indeterminate Colitis: high chance may be Crohn's, however still worth considering as an option in right clinical setting
- Crohn's: NOT an indication, however patients incorrectly diagnosed have found to have a favorable long term outcome with their pouch
- FAP: over age 20, no effect on small bowel CA risks

Contraindications:

- Crohn's:
- Advanced low lying rectal CA
- poor sphincter function

Timing of Surgery:

- 90% staged
- ileostomy reversal 3 months later
- preop gastrograffin enema & pouch endoscopy

Surgical Technique:Main Steps:

1. Total Abdominal Colectomy
2. Proctectomy
3. Construction of ileal pouch
4. Ileoanal Anastomosis
5. Diverting loop ileostomy

Proctectomy:

- Stay anterior to Waldeyer:
 - avoid nervi erigents & presacral veins
- Stay posterior to Denonvilliers Fascia
 - autonomic nerve plexus anterior to this
- If not for dysplasia, do close rectal dissection to preserve the autonomic nerve plexus
- Firm Traction crucial for visualization of planes
- Middle rectal vessels large in ~4.8% of patients
- Mobilization to level of the levator plate
- Once specimen removed, place a pack to tamponade veins
- *Examine* specimen, make sure not Crohn's of cancer

Pouch Design:

- J-pouch: 15-20 cm in length
 - J easier to construct and equal outcome to S & W pouches
- pouch capacity increase to 2-4x initial at 1 yr post
- S-pouch gives ~2 cm more length, alternative when length an issue (short fat mesentery w/ long narrow pelvis)

Mobilize small bowel – if too short, steps:

- dissect to 3rd portion of duo
- ligate ileocolic artery at origin
- transverse incisions over superior mesenteric vessels

Stapled vs. Handsewn?

- essentially a question of: mucosectomy or not?
- Pros Stapled:
 - better fxn'l result, decrease sepsis, easier

- Disadvantage: local recurrence rates higher
- Prospective randomized trials have shown no difference
 - but have had short term follow up, and small series
 - vulnerable to type II error
- Cleveland Clinic's Rec: mucosectomy if:
 - CA in lower 2/3
 - poor compliance/follow up patients
 - FAP with significant polyps at transition zone

TransAnal insufflation at the end to test anastomosisIleostomy:

- about 20-25 cm proximal to the pouch
- can be omitted in optimal patients

Postop Mgmt

- common for high output ostomy for these patients
 - be aware of dehydration
 - salty soups and electrolyte supplements
 - avoid high solid fiber/indigestible foods for 6 weeks
 - loperamide, atropine sulfate, etc. may be needed to thicken effluent
 - psyllium bulking agents
- taper steroids (disease out)
- f/u 4-6 weeks – evaluate with enema and endoscopy
 - check sphincter strength
 - patient's control of mucus discharge
 - if in doubt: enema challenge (can hold 100 ml saline enema?) and manometry to evaluate

Reported Outcomes (Cleveland Clinic)

- 30 day operative mortality: 0.2%
- Morbidity: 60%
- Anastomotic Leak: 5%
- Small Bowel Obstruction: 20%
 - 6% of these needed reop
- Five year pouch survival: 95.6%
- Pouch removed in 3.4%
- Pouch Non-functional: 1%
 - Pouch Failure rate: 4.4%
- Independent risk factors of pouch survival:
 - Crohn's, prior anal pathology, post op pouch fistulae, pelvic sepsis, anastomotic stricture
- Pouchitis: 30%
 - increased infertility rate in women

Ileostomy Takedown: 11% complication ratePouchitis:

- Sx: increased stooling, urgency & cramps
 - blood per rectum: only in cuffitis, not pouchitis
- Rx: 2 weeks cipro & flagyl
 - Rx for Cuffitis: topical hydrocortisone and mesalamine

Bowel Frequency

- ~ six times per day after a year
- continence for stool & flatus in 70% at night, 80% day
- major fecal incontinence in 5%

Ligation of Intersphincteric Fistula Tract (LIFT)

- Prone Jack Knife Position
- Local Anesthetic block
- Local with epi into intersphincteric plane
- Place Fistula probe into and through entire tract, exteriorize internal part of probe
- Mark intersphincteric plane ~2 cm wide incision
- Dissect intersphincteric plane down to fistula tract where probe is in place
- Develop plane behind the probe
- Vessel loop snapped at both sides of probe
- Remove fistula probe with vessel loops holding tract out
- Suture closed the tract with ligating sutures at internal and external opening
- Divide the tract
- With hydrogen peroxide, test the opening exteriorly to ensure that there is no residual defect
- Close the intersphincteric plane with interrupted sutures
- Close cutaneous defect with interrupted sutures

Gracilis Flap Notes

1. Lithotomy position
 - if s/p APR, may consider completing most posterior part of closure of perineum in prone to aid in closure
2. Prep and drape both legs to the knee
3. Palpate the from the pubis – the narrow tight muscle you can palpate is the *Adductor Longus* – mark here
4. Mark two finger breadths below the *Adductor Longus*
 - Origin of Gracilis is here
5. Draw a line from your point to the knee – path of Gracilis
 - proximal incision should be about 6-7 cm long
 - distal incision ~3 cm long
6. Dissect through subcutaneous tissue – the most superficial muscle you should encounter should be the gracilis
7. Isolate its vascular pedicle:
 - will be on posterior lateral aspect (between it and *Add Longus M.*) about 4-5 cm from the most proximal part of your incision
 - ligate branching vessels, but preserve the main pedicle
8. Dissect the muscle free from surrounding structures and fascia
9. Make distal most incision – can use a deaver or your finger subcutaneous from proximal incision to show you the precise location to cut distally
10. Transect the muscle distally
11. pass the muscle through the subcutaneous tunnel
12. Develop a subcutaneous tunnel to your perineal wound
 - this is a superficial tunnel
 - caution not to button hole
13. Place flap into cavity/around sphincters
14. Close incisions in two layers (staples ok)
15. Two drains recommended, one for leg, one for cavity
16. Wrap leg with ace wrap (keep on for two days)
17. Post op: restrict from sitting up for 1-2 weeks

Rectocele Repair with Mesh

- Lithotomy Position
- Local Anesthetic block
- double glove one hand (with several extra outer gloves) and palpated from the rectum the defect
 - Every time you bring the hand out of rectum, remove glove and replace with new one
- Transvaginally marcate with bovie burns the perimeter of the defect and the area of vagina to be excised
- Transvaginally, cephalad to the sphincters, begin incision in the vagina and find the rectovaginal septum plane
- Use alics clamps to help elevate the vaginal specimen and demonstrate the plane
- Using previously marked boundaries – continue dissection up towards the cervix. A deaver may assist with visualization deep into vaginal vault.
- Ensure to stay clear of rectal serosa as to prevent perforation of the rectum
- The vaginal dissection should be freely dissected and passed off the field (specimen or trash)
- Dissection continues such that fascia overlying the levator plate is clearly visible
- Flaps of about 1-2 cm should be created of the vaginal to rectal surface circumferentially
- Pelvicol (Permacol, but smaller size) sutured into the space
 - Start with two cephalad sutures below cervix that tack it into place
 - Interrupted sutures circumferentially, vicryls
 - Should have at least 1 cm overlap with edges
 - ALL of these sutures are permacol to the levator fascia
- Re-approximate vaginal mucosa with full thickness bites of interrupted vicryls
- Vaginal packing with clindamycin vaginal cream to assist with bleeding

Key points:

- stay in the right plane
- stop all bleeding to prevent hematoma which could cause wound breakdown

Sacral Nerve Stimulation for Fecal Incontinence

Wexner et al:

Prevalence: 1-2%

- frequent cause of nursing home in elderly

Long term follow up of sphincteroplasty ~40% success rate

More aggressive approaches:

- Artificial Bowel Sphincter
- Dynamic Graciloplasty (not US approved)
- permanent fecal diversion

Study design:

- multi-center trial at 16 centers

Study Goal:

- >50% of pt's to get >50% reduction in symptoms at 1 yr
- fecal diary during this time

Patients:

- FI > 6 months of >2 episodes per week
- all failed dietary modification
- all failed biofeedback
- Exclusion: congenital defects, previous rectal surgery in last 2 years, defects >60 degrees, pelvic radiation effects that were visible, IBC sequelae, unmanageable loose stools, pregnancy or planned pregnancy, dementia

Procedures:

Studies:

- anorectal manometry, PNTML, EUS, FI score, Bowel diary;
- follow up at 1 mo, 3 mo, 6 mo, 12 mo, Q1yr

Operative Technique:

- staged – electrode in S2-4 – connected to test stimulator
- tested for 10-14 days
- successful if diary showed >50% reduction
- external stimulator replaced with subQ port
- electrode variables:
 - pulse width 210 microseconds
 - frequency 15 Hz
 - continuous or cyclical stimulation
 - stimulation voltage above perception

Results:

- 83% success at 12 months
- 85% at 2 years
- patients with sphincter defect showed improvement

Hetzer et al

Operative Technique: 2 phase implant

Phase 1: percutaneous nerve 2-3 weeks – if showed >50% reduction, then to phase 2

- prophylactic ancef/flagyl
- can be done under local

Complications: infection, seroma, perineal pain, sleep disturbance, leg pain

Results: 77% success rate, of permanents, 92% success

OPERATIVE TECHNIQUE*Phase I*

1. Prone Position
2. Sacral area prepped and landmarks are marked
3. Local anesthesia applied
4. Insulated needle into S3-S4 foramen – identification of sensory and motor response
 - *Sensory:* vibraoty feeling or pulling sensation on vagina or rectum
 - *Motor:* tightening of the levators, plantar flexion of the great toe
5. insulated wire inserted through the needle, and then needle is removed
6. Wire taped into place and attached to external simulator
7. Voiding diary for 10-14 days – goal >50% improvement

Phase II

1. Prone Position
2. Antibiotic prophylaxis
3. midline sacral incision made
4. carried down to the level of lumbodorsal fascia – opened to about 1.5 cm from midline
5. paravertebral muscles separated and divide and sacral periosteum identified
6. Insulated needle placed into sacral foramen and they are tested
7. once appropriate foramen found, sutured into place
8. tunneling tool to transfer free end
9. incision closed in layer, no drains left
10. PXR to confirm placement before discharge